

# Long Term Outcome of McIndoe's Technique for Vaginal Agenesis & Effect on Quality of Life, Sexual Function & Body Image

Dr. Sushree Jagadeb M.D (O&G)<sup>1</sup>, Dr. Suryakanta Bisoi MCh (Plastic Surgery)<sup>2</sup>

<sup>1</sup>Senior Resident, Department of Obstetrics & Gynaecology, S.C.B Medical College, Cuttack, Odisha, India

<sup>2</sup>Senior Resident, Department of Plastic & Reconstructive Surgery, S.C.B Medical College, Cuttack, Odisha, India

**Abstract:** Vaginoplasty is a surgical procedure whose purpose is to treat vaginal structure defect. Vaginal agenesis is estimated to occur in 1 in 4,000-5,000 live female births. These patients are usually managed by different surgical procedure but the long-term outcome is controversial. Among various methods McIndoe technique has remained most popular, here split thickness skin graft is used to line the neovagina. The main advantages are its simplicity and low morbidity. The disadvantages are graft contraction, fistula formation and need for long-term use of vaginal retainer.

**Keywords:** Vaginal atresia, McIndoe's Vaginoplasty, Split thickness skin graft, Sponge/foam Mold

## 1. Introduction

Vaginoplasty is a surgical procedure whose purpose is to treat vaginal structure defect. The McIndoe Vaginoplasty is indicated in patients with congenital absence of the vagina, in patients whose vagina must be removed, and in patients with severe stenosis following irradiation therapy. A split-thickness skin graft has traditionally been utilized with this operation.

Vaginal agenesis is estimated to occur in 1 in 4,000-5,000 live female births. These patients are usually managed by different surgical procedure but the long-term outcome is controversial. Among various methods McIndoe technique has remained most popular, here split thickness skin graft is used to line the neovagina. The main advantages are its simplicity and low morbidity. The disadvantages are graft

contraction, fistula formation and need for long-term use of vaginal retainer.

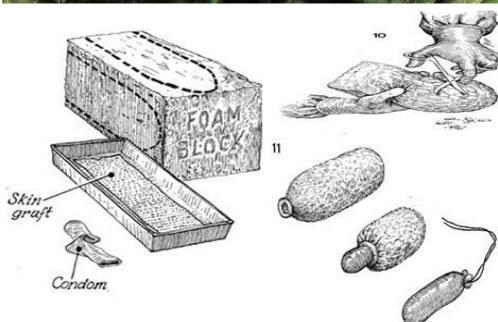
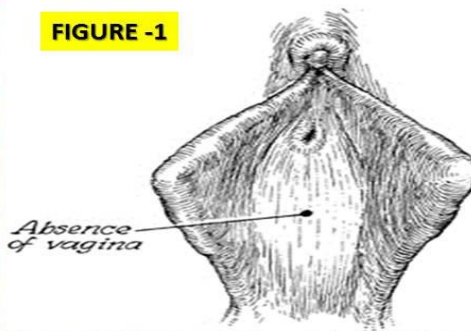
The Present study has been designed to find out the outcome of vaginoplasty done by McIndoe method where a skin graft on a mold made by sponge and condom has been used for long period to maintain the space and to allow skin graft to takeup. Eleven patients with vaginal agenesis were included.

## 2. Surgical Procedure

A transverse incision was given on the introitus and then a space was created in between the urethra and bladder in front and rectum behind by blunt finger dissection. The created space is about 12 cm in length and 5 cm in diameter. An intermediate thickness split skin graft was taken from posterior aspect of either thigh & pie-crusting (multiple small holes) done (Figure-1).

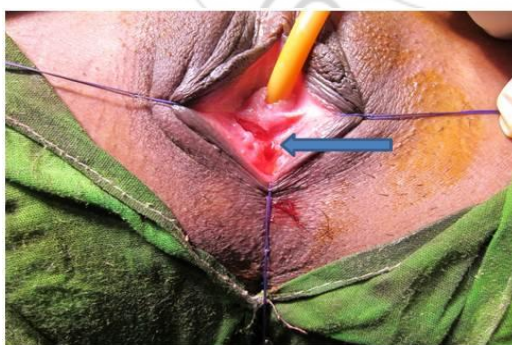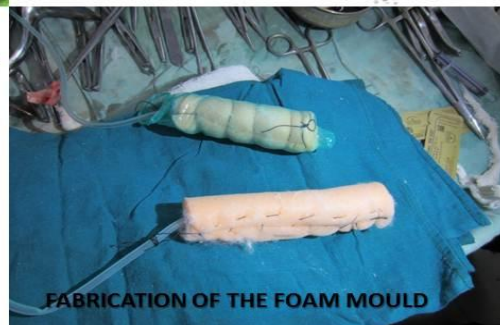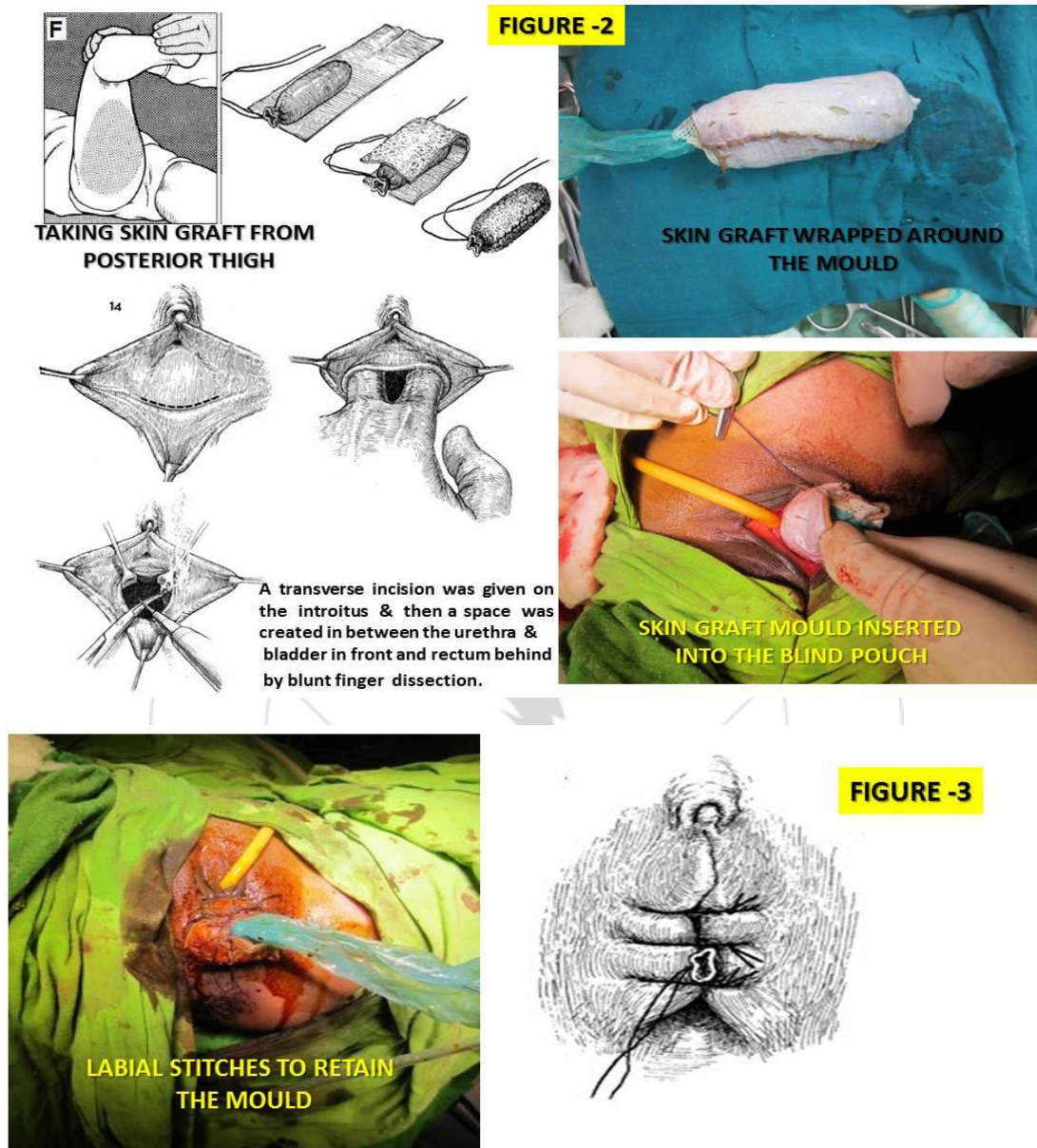


FIGURE -1



A mold made by sponge and condom was created & skin graft placed over the mound & put in the newly created space. The vaginal mold should be soft and flexible. Sponge mold confined to a condom has produced a soft vaginal mold that expands against the graft in a gentle manner without producing points of pressure (figure-2). Excessive

pressure could produce necrosis with possible vesicovaginal or rectovaginal fistula formation. 2-3 stitches (figure-3) were given through the inner aspect of the labia over the mold so the mold could not come out.



After 5 days mold was removed. Another freshly prepared mold was placed in the space as before. All the process was repeated weekly for another two/three times. Then the

patients were asked to wear the mold continuously for three months and then at night for another three months. Thereafter they were advised for daily dilatation with the



mold or practiced regular coitus. Married women were allowed to perform physical relation after 6 weeks. The patients were advised to come for follow-up after 1 month, 3 month and 6 month.

### 3. Method/Approach/Study Design

The purpose of this study was to evaluate quality of life, sexual function, and long-term outcome in women after undergoing the McIndoe procedure for vaginal agenesis. This was a retrospective descriptive study of patients who were treated with the McIndoe procedure for vaginal agenesis. Participants answered a structured questionnaire to describe self-reported outcomes in quality of life, sexual function and satisfaction, and body image after the McIndoe procedure. Patient characteristics along with short- and long-term findings were abstracted from the medical record.

### 4. Discussion

From historical perspective, a variety of non surgical as well as surgical procedures to correct vaginal agenesis have been described. The Frank's technique involves sequential dilatation of the vaginal remnant. The Frank's method is non-surgical however its success has proven variable and unpredictable. The patient needs to be highly motivated and willing to continue long term dilatation. However, awkward positioning and tediousness, possibility of vaginal prolapse, stenosis and eversion are the major drawbacks of this method .8

There are various methods for surgically constructing neovaginas and the difference among the various surgical approaches lies in the tissues used to line the neovagina. The various techniques described are Abbe-McIndoe, McIndoe and Bannister procedure constructing neovagina from bowel segments, pudendal-thigh flaps, fasciocutaneous flaps, gracilis myocutaneous flap, labia minora flaps, flaps raised following tissue expansion of the labial pocket, peritoneum and bladder mucosa, amnion and autologous buccal mucosa graft.

The reconstruction with flaps involves technically complex techniques. Musculocutaneous flaps are sturdy and the gracilis and rectus being the most commonly used muscles. These flaps are sensate but bulky and hairy and require larger dissection to create an adequate space between rectum and the bladder. This bulk is quite often helpful in vaginal reconstruction after radical operations for cancer or after irradiation, but are not the procedure of choice in patients with MRKH syndrome. The failure rate of gracilis flap is high because of tenuous vascularity of the flaps. In pudendal flaps problem is of dehiscence, infection and drainage.

Vecchietti's method and modifications of similar laparoscopic procedure are complicated and technically demanding. All these techniques are associated with discomfort and requires a long period for adequate results. Bowel vaginoplasty utilizing sigmoid colon offers some advantages over skin grafts because of distensibility and self-lubricating property with no tendency for neovagina stenosis but has the drawbacks of a laparotomy with visible scars, possibility of bowel leakage/obstruction and problem of mucous secretion.

Autologous buccal mucosa has also been attempted as graft material encouraging results obtained for neovaginoplasty in few studies. However these studies comprised of limited number of patients with no long term follow-ups. Out of the many different approaches available for vaginal reconstruction, the technique proposed by McIndoe has remained till now the most popular and the safest technique for treatment of vaginal agenesis.

### 5. Results

All the 11 patients responded to the questionnaire. Forty percent patients were married. Average age ( $\pm$ SD) at surgery was  $22 \pm 7$  years (range, 16-34 years). Sixty-nine percent (69%) of the respondents stated that the McIndoe procedure improved their quality of life.

Ninety-one percent (89%) of the respondents were sexually active, with 65% able to achieve orgasm. Reported self-image was improved in 45% of the women.

### 6. Conclusion

The McIndoe procedure improves quality of life and sexual satisfaction and provides a functional vagina with minimal complications.

### References

- [1] Capraro VJ, Gallego MB. Vaginal agenesis. *Am J Obstet Gynecol* 1976; 124: 98-107.
- [2] Tolhurst DE, van der Helm TW. The treatment of vaginal atresia. *Surg Gynecol Obstet* 1991; 172(5): 407-14.
- [3] Hojsgaard A, Villadsen I. McIndoe procedure for congenital vaginal agenesis: complications and results. *Br J Plast Surg* 1995; 48(2):97-102.
- [4] Griffen JE, Creighton E, Madden JD, Harrod MJ, Wilson JD. Congenital absence of the vagina: the Mayer-Rokitansky-Küster-Hauser syndrome. *Ann Intern Med* 1976; 85:224-236.
- [5] Mobus VJ, Kortenhorn K, Kreienberg R, Freidberg V. Long term results after operative correction of vaginal aplasia. *Am J Obstet Gynecol* 1996; 175:617-624.
- [6] Frank R.T: The formation of an artificial vagina without operation. *Am Obstet Gynecol* 1938; 35:1053- 5.
- [7] Ashworth MF, Morton KE, Dewhurst J, Lilford RJ, Bates RG. Vaginoplasty using amnion. *Obstet Gynecol*, 1986; 67:443-446.
- [8] Buss JG, Lee RA. McIndoe procedure for vaginal agenesis: results and complications. *Mayo Clin Proc* 1989; 64(7):758-61.
- [9] McIndoe AH, Bannister JB. An operation for the cure of congenital absence of the vagina. *J Obstet Gynaecol Br Emp* 1938; 45: 490- 494.
- [10] McIndoe A. The treatment of congenital absence and oblitative conditions of vagina. *Br J Plast Surg* 1950; 2:254-67.
- [11] Burger RA, Reedville H, Knapstein PG, Friedberg V, Hohenfellner R. Ileocecal vaginal construction. *Am J Obstet. Gynecol* 1989; 161:162-167.

- [12] Franz RC. Sigmoid colon vaginoplasty: a modified method. *Br J ObstetGynecol* 1996; 103:1148-1155.
- [13] Hensley TW and Reiley EA. Vaginal replacement in children and young adults. 1998 *J Urol*; 159:1035-1038.
- [14] Joseph VT. Pudendal-thigh flap vaginoplasty in reconstruction of genital anomalies. 1997 *J PediatrSurg*; 32: 62-65.
- [15] Morton KE, Davies D, Dewhurst J. The use of the fasciocutaneous flap in vaginal reconstruction. 1986 *Br J ObstetGynecol*; 93: 970.
- [16] Mc-Craw JB, Massey FM, Shanklin KD. Vaginal reconstruction with gracilis myocutaneous flaps. *PlastReconstrSurg* 1976; 52:176-83.
- [17] Flack CE, Barraza MA, and Stevens PS. Vaginoplasty: combination therapy using labia minora flaps and Lucite dilators: a preliminary report. *J Urol* 1993; 150: 654-656.
- [18] Chudacoff RM, Alexander J, Alvero R. and Segars JH. Tissue expansion vaginoplasty for treatment of congenital vaginal agenesis. *ObstetGynecol* 1996; 87:865-868.
- [19] Martinez-Mora J, Isnard R, Castellvi A., Lopez OP. Neovagina in vaginal agenesis: surgical methods and long-term results. *JPediatrSurg* 1992; 27:10-14.
- [20] Soong YK, Chang FH, Lai YM, Lee CL, Chou HH. Results of modified laparoscopically assisted neovaginoplasty in 18 patients with congenital absence of vagina. *Hum Reprod* 1996; 11: 200-203.
- [21] Nisolle M and Donnez J. Vaginoplasty using amniotic membranes in cases of vaginal agenesis or after vaginectomy. *JGynecolSurg* 1992; 8:25-30.

