

44

Paravaginal Repair: A Laparoscopic Approach

John R. Miklos and Robert Moore

Atlanta Urogynecology Associates, Atlanta, Georgia, U.S.A.

Neeraj Kohli

Harvard University, Boston, Massachusetts, U.S.A.

I. INTRODUCTION

The support of the anterior vaginal wall, with its overlying bladder and urethra, is dependent upon the inherent strength of the pubocervical fascia and its lateral attachment to the pelvic sidewalls. Specifically, the pubocervical fascia is attached to the arcus tendineus fascia pelvis (also termed "the white line"). The arcus tendineus fascia pelvis is a condensation of intervening connective tissue overlying the obturator internus muscle (Fig. 1). Upon vaginal inspection the anterior lateral vaginal sulcus shows excellent support when the pubocervical fascia and the arcus tendineus are intact (Fig. 2). Loss of the lateral vaginal attachment to the pelvic sidewall is called a paravaginal defect and usually results in a cystourethrocele, urethral hypermobility, and/or stress urinary incontinence (Fig. 3). Vaginal inspection in patients with bilateral paravaginal defects reveals loss of anterior vaginal wall support with detachment of the lateral sulci, resulting in a displacement cystocele (Fig. 4). White (1) first described the paravaginal repair in 1909, but it did not gain popularity until decades later, when Richardson (2,3) and Shull (4,5) described their abdominal and vaginal approaches to this type of anterior wall repair. Paravaginal defect repair has been described using not only vaginal and open abdominal approaches but also, more recently, via a laparoscopic approach (6–8).

II. OPERATIVE INDICATIONS

Laparoscopy should be considered as only a mode of abdominal access and not a change in the operative technique. The surgical repair of paravaginal defects should not be different whether the approach is vaginal, abdominal, or laparoscopic. Ideally, the indications for a laparoscopic approach to paravaginal defect repair should be the same as an open abdominal approach. The laparoscopic approach to paravaginal defect repair can be substituted for an open paravaginal repair in the majority of cases. Factors that might influence this decision include previous abdominal, pelvic or anti-incontinence surgery, the patient's weight, the need for concomitant surgery, and the surgeon's experience. The surgeon's decision to proceed with a laparoscopic paravaginal repair should be based on an objective clinical assessment that is consistent with a paravaginal defect cystocele or cystourethrocele, as well as the surgeon's own surgical skills. The paravaginal repair can be performed alone or in combination with a urethropexy procedure in patients with concomitant stress urinary incontinence.

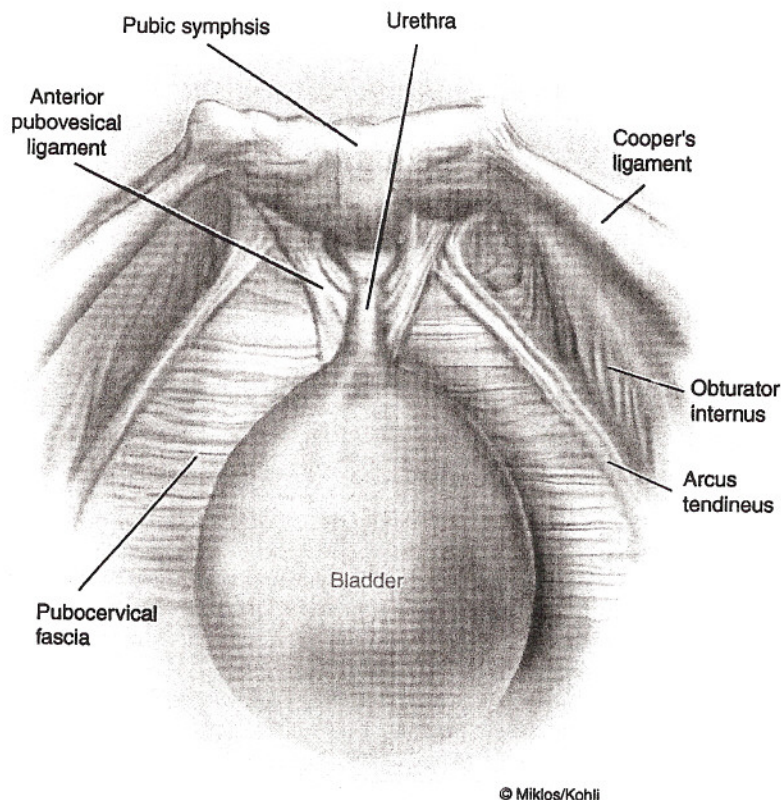


Figure 1 Normal anterior vaginal wall support (aerial view). The space of Retzius and normal anterior vaginal wall support.

III. PREOPERATIVE CONSIDERATIONS

A bowel preparation should be considered in any patient undergoing advanced reconstructive pelvic surgery. The authors recommend a full liquid diet 48 h prior to surgery, and a clear liquid diet and one bottle of magnesium citrate 24 h before surgery. This regimen appears to improve operative field visualization by bowel decompression and reduces the chance of contamination in case of accidental bowel injury. A single dose of prophylactic intravenous antibiotics is administered 30 min before surgery. Antiembolic compression stockings are routinely used. The patient is intubated, given general anesthesia, and placed in dorsal lithotomy position with both arms tucked to her side. A 16F three-way Foley catheter with a 5-mL balloon tip is inserted into the bladder and attached to continuous drainage. The authors find that a 30-cc balloon tip filled to capacity actually will hinder visualization and suture placement, especially paraurethrally.

IV. SURGICAL TECHNIQUE

The technique of abdominal entry and insufflation is a matter of surgeon's preference. The authors routinely perform open laparoscopy at the inferior margin of the umbilicus. A 10-mm access port is inserted to introduce the laparoscope. The abdomen is insufflated

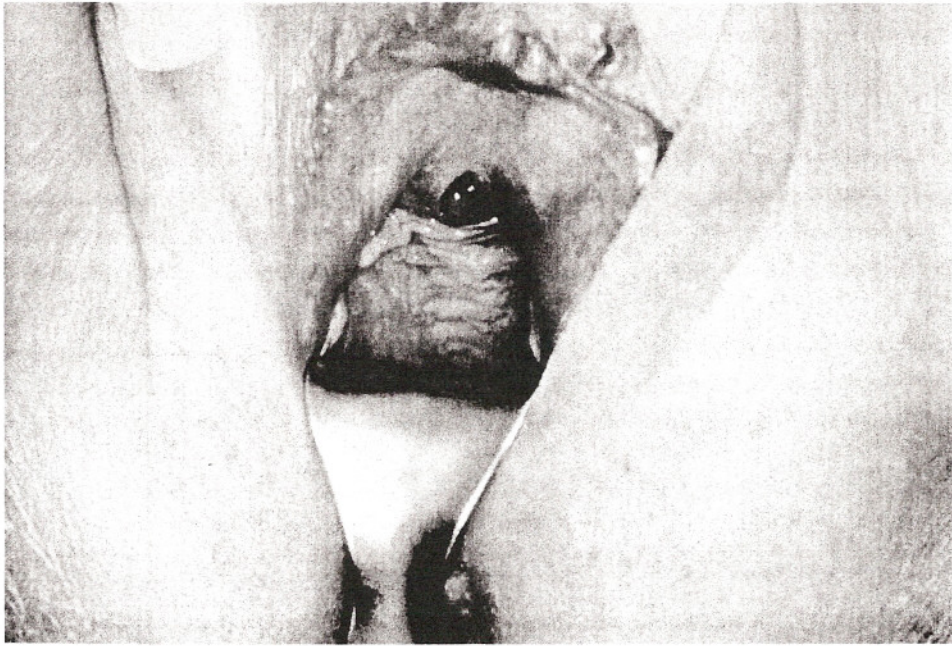


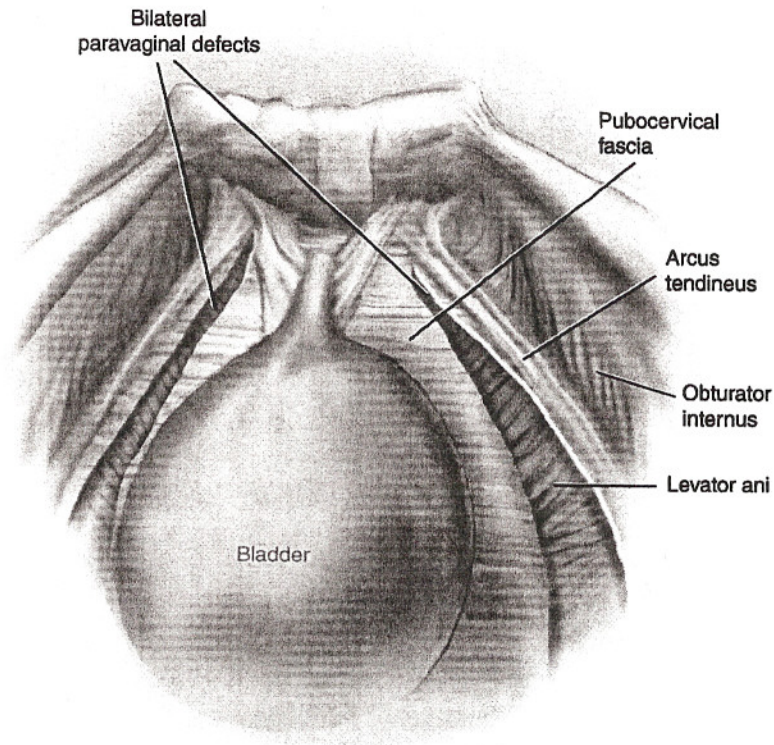
Figure 2 Normal anterior vaginal wall support (vaginal exam). The anterior vaginal wall is well supported with normal lateral fornix attachment.

with CO₂ to 15 mm Hg intra-abdominal pressure. Three additional ports are placed under direct vision (Fig. 5). The type of port, choice of port size, and placement depend upon the planned concomitant surgery as well as the surgeon's preference.

The bladder is filled in a retrograde fashion with 200–300 mL of sterile water, allowing identification of the superior border of the bladder edge. A harmonic scalpel is used to incise the peritoneum ~3 cm anterior to the bladder reflection, between the obliterated umbilical ligaments (Fig. 6). Identification of loose areolar tissue confirms a proper plane of dissection.

After the space of Retzius has been entered and the pubic ramus visualized, the bladder is drained to prevent injury. Using blunt dissection the retropubic space is developed by separating the loose areolar and fatty layers. Blunt dissection is continued until the retropubic anatomy is visualized. The pubic symphysis and bladder neck are identified in the midline and the obturator neurovascular bundle, Cooper's ligament, and the arcus tendineus fascia pelvis (white line) are visualized bilaterally along the pelvic sidewall (Fig. 1). The anterior vaginal wall and its point of lateral attachment from its origin at the pubic symphysis to its insertion at the ischial spine are identified. If paravaginal wall defects are present, the lateral margins of the pubocervical fascia will be detached from the pelvic sidewall at the arcus tendineus fascia pelvis. The lateral margins of the detached pubocervical fascia and the broken edge of the white line can usually be clearly visualized confirming the paravaginal defect. Unilateral or bilateral defects may be present (Fig. 3).

After identification of the defect, the repair is begun by inserting the surgeon's nondominant hand into the vagina to elevate the anterior vaginal wall and the pubocervical fascia to their normal attachment along the arcus tendineus fascia pelvis. A 2-0 nonabsorbable suture with attached needle is introduced through the 12-mm port and the needle is grasped using a laparoscopic needle driver.



© Miklos/Kohli

Figure 3 Paravaginal defects (aerial view). Loss of lateral vaginal attachment at the arcus tendineus, resulting in a cystourethrocele.

The first suture is placed near the apex of the vagina through the paravesical portion of the pubocervical fascia. The needle is then passed through the ipsilateral obturator internus muscle and fascia around the arcus tendineus fascia at its origin 1–2 cm distal to the ischial spine. The suture is secured using an extracorporeal knot-tying technique. Good tissue approximation is accomplished without a suture bridge. Sutures are placed and tied sequentially along the paravaginal defects from the ischial spine toward the urethra. Usually a series of four to six sutures are required to repair the paravaginal defect unilaterally. The surgical procedure is then repeated on the opposite side if a bilateral paravaginal defect is present. Paravaginal defect repairs restore anterior vaginal wall lateral attachment and support (Fig. 6). However, paravaginal defect repair has little support in the literature for treatment of stress urinary incontinence. If a patient has concomitant stress urinary incontinence, a laparoscopic urethropexy procedure can be performed after the paravaginal repair.

The urethropexy will focus on the distal aspect of the anterior vaginal wall and the paravaginal repair will anatomically restore and support the proximal (bladder) portion of the anterior vaginal wall. Instead of placing four to six paravaginal sutures on each side as previously described, the proximal paravaginal repair, between the ischial spine and the urethrovesical junction, usually only requires two or three sutures on each side. This portion of the surgery should repair the cystocele but will do nothing to support the urethra and its coexisting stress urinary incontinence. The authors recommend coupling a Burch urethropexy with the

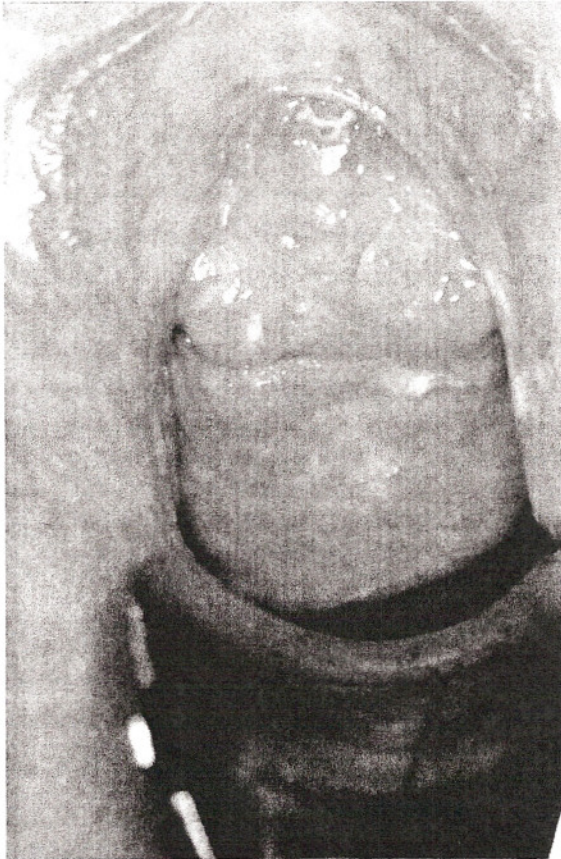

Figure 4 Paravaginal defects (vaginal exam). Loss of lateral vaginal attachment at the arcus tendineus, resulting in a cystourethrocele.

paravaginal repair to address the incontinence. A total of four sutures should be placed to complete the Burch urethropexy: two sutures bilaterally, one paraurethrally at the midurethra, and the other at the urethral vesical junction (Fig. 8). By coupling the Burch urethropexy with the paravaginal repair, the surgeon can address both the proximal cystocele and the distal urethral hypermobility and its coexisting stress urinary incontinence.

Upon completion of the Burch and/or paravaginal repair the intra-abdominal pressure is reduced to 10–12 mm Hg, and the retropubic space is inspected for hemostasis. Cystoscopy is performed to rule out urinary tract injury. The patient is given 5 mL of Indigo Carmine and 10 mL of furosemide intravenously, and a 70° cystoscope is used to visualize the bladder mucosa, assess for unintentional stitch penetration and bladder injury, and confirm ureteral patency. After cystoscopy, attention is returned to laparoscopy. The authors recommend routine closure of the anterior peritoneal defect using an absorbable suture or a multifire hernia stapler. All ancillary trocar sheaths are removed under direct vision to ensure hemostasis and exclude iatrogenic bowel herniation. Excess gas is expelled and fascial defects of 10 mm or more are closed using delayed absorbable suture. Skin edges are closed using an absorbable suture. Post-operative bladder drainage and voiding trials are accomplished using a transurethral catheter, suprapubic tube, or intermittent self-catheterization.

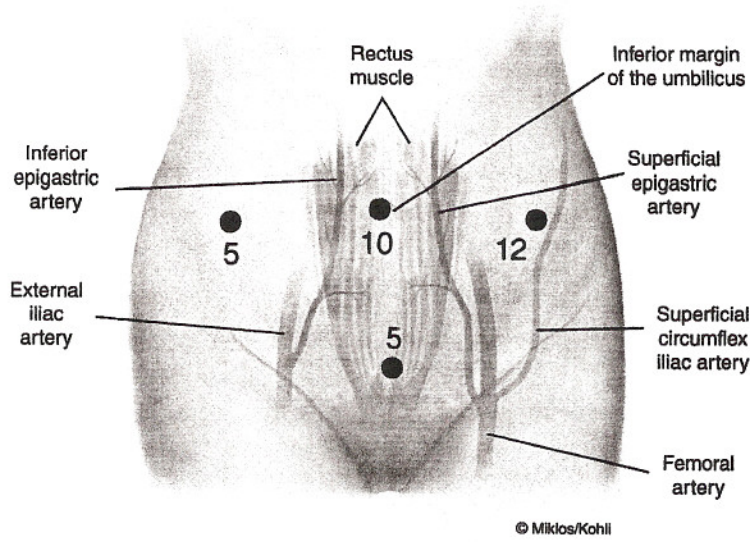


Figure 5 Laparoscopic incision sites. Port size and placement are illustrated.

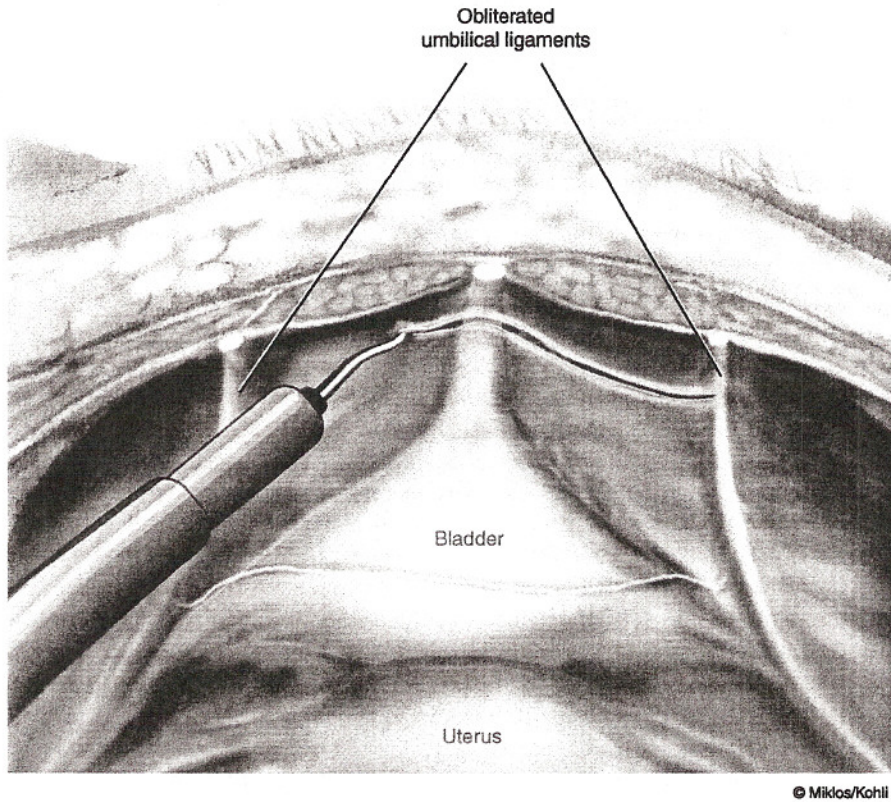


Figure 6 Peritoneal incision. Using a harmonic scalpel to incise the peritoneum between the obliterated umbilical ligaments and anterior to the bladder.

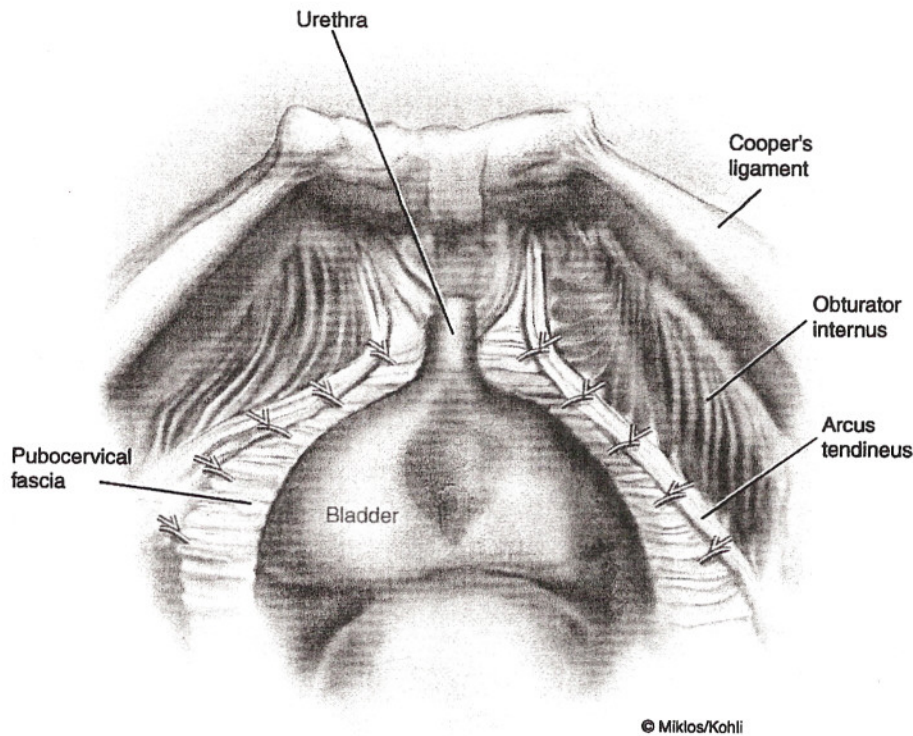


Figure 7 Paravaginal repair: conventional repair of paravaginal defects. Nonabsorbable suture is used to reapproximate the pubocervical fascia (i.e., anterior vaginal wall) back to its original point of lateral attachment, known as the arcus tendineus fascia pelvis (i.e., “white line”).

V. CLINICAL RESULTS

Most studies reporting the efficacy of paravaginal repair in the treatment of genuine stress incontinence, whether performed vaginally or abdominally, lack appropriate outcome data and control groups. In a randomized prospective trial, Colombo et al. (12) performed Burch colposuspension on 18 patients and abdominal paravaginal repair on 18 patients with genuine stress incontinence. Patients undergoing Burch colposuspension had a significantly higher subjective (100% vs. 72%; $P = 0.2$) and objective (100% vs. 61%; $P = 0.04$) cure rates compared with patients undergoing paravaginal repair. The study was discontinued early because the authors no longer regarded it as ethical to propose paravaginal repair for the treatment of stress urinary incontinence (13). Specifically, data regarding the efficacy of laparoscopic paravaginal repair are also limited. Ostrzenski (14) performed laparoscopic paravaginal repair in 28 women with stress urinary incontinence. The subjective cure rate was 93% with follow-up ranging from 1 to 4.5 years. Pre- and postoperative urodynamic testing were not utilized. Given a patient has concomitant stress urinary incontinence with anterior vaginal wall prolapse due to paravaginal defects, the authors recommend coupling the paravaginal repair with a proven anti-incontinence operation such as a Burch urethropexy or a transvaginal sling.

Most surgeons utilize the paravaginal repair for the correction of anterior vaginal wall prolapse and do not rely on this operation for the treatment of stress urinary incontinence.

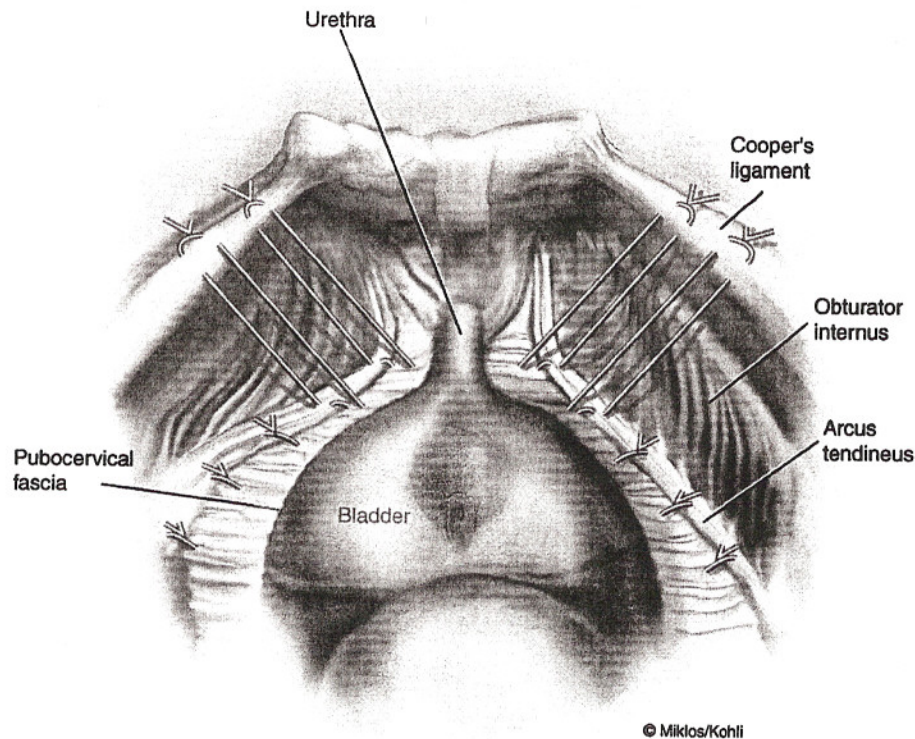


Figure 8 Paravaginal plus Burch urethropexy. The paravaginal sutures are placed to restore anatomy and correct the proximal cystocele, and four additional paraurethral suspension sutures (i.e., Burch urethropexy) are placed in patients diagnosed with stress urinary incontinence.

Paravaginal repair is an anatomically correct operation for the treatment of anterior vaginal wall prolapse due to paravaginal defects. As described above, the objective of the paravaginal repair is to reattach the anterolateral vaginal sulcus to the obturator internus muscles and fascia at the level of the white line. Anterior vaginal wall prolapse cure rates >95% have been reported utilizing the abdominal approach (2–4), and >90% utilizing the vaginal (5,9–11) approach to paravaginal repair. Literature concerning the efficacy of the laparoscopic paravaginal repair for the cure of anterior vaginal wall prolapse is lacking. A recent review of our experience (15) revealed that 130 of 171 patients had a Burch urethropexy and paravaginal repair, 23 of 171 patients a Burch urethropexy alone, and 18 of 171 patients a paravaginal repair alone. Of the authors' 171 patients, four (2.3%) had injury to the lower urinary tract during laparoscopic Burch urethropexy or paravaginal repair. All four injuries were cystotomies, two in patients with previous open retropubic urethroplexies. No ureteral ligations or intravesical placement of suture was diagnosed. Other surgical parameters for the laparoscopic Burch urethropexy and paravaginal repair include an estimated blood loss of 50 mL, average hospital stay of <23 h, and an average operative time of 70 min. All patients had their surgery completed via laparoscopy.

Assuming that the paravaginal repair technique is not compromised by the abdominal approach utilized (laparoscopic vs. laparotomy), one should expect equal surgical efficacy.

VI. CONCLUSION

Defects in the lateral attachment of the pubocervical fascia to the arcus tendineus fasciae pelvis results in anterior vaginal wall prolapse and subsequent cystocele. The literature supports the use of paravaginal repair in the treatment of anterior vaginal wall prolapse but does not support its use for the treatment of stress urinary incontinence.

The authors support the use of the laparoscopic paravaginal repair in the treatment of cystocele or cystourethroceles in patients with lateral anterior vaginal wall defects. The laparoscopic approach to paravaginal defect repair can be substituted for an abdominal or transvaginal paravaginal repair in the majority of cases. Factors that might influence this decision include previous abdominal, pelvic or anti-incontinence surgery, patient's weight, the need for concomitant surgery, and the surgeon's experience. The paravaginal repair can be performed alone or in combination with a urethropexy procedure in patients with concomitant stress urinary incontinence.

REFERENCES

1. White GR. Cystocele, a radical cure by suturing lateral sulci of vagina to white line of pelvic fascia. *JAMA* 1909; 65:286–290.
2. Richardson AC, Lyon JB, Williams NL. A new look at pelvic relaxation. *Am J Obstet Gynecol* 1976; 126:568–573.
3. Richardson AC, Edmonds PB, Williams NL. Treatment of stress urinary incontinence due to paravaginal fascial defects. *Obstet Gynecol* 1981; 57:357–361.
4. Shull BL, Baden WF. A six year experience with paravaginal defect repairs for stress urinary incontinence. *Am J Obstet Gynecol* 1989; 160:1432–1437.
5. Shull BL, Benn SJ, Kuehl TJ. Surgical management of prolapse of the anterior vaginal sement: an analysis of support defects, operative morbidity and anatomic outcome. *Am J Obstet Gynecol*. 1994; 171:1429–1439.
6. Miklos JR, Kohli N. Paravaginal plus Burch procedure: a laparoscopic approach. *J Pelvic Surg* 1998; 4:297–302.
7. Miklos JR, Kohli N. Laparoscopic paravaginal repair plus Burch colposuspension: review and descriptive technique. *Urology* 2000; 56:64–69.
8. Ross JW. Techniques of laparoscopic repair of total vault eversion after hysterectomy. *J Am Assoc Gynecol Laparosc* 1997; 4(2):173–183.
9. Elkins TE, Chesson RR, Videla F, Menefee S, Yordan R, Barksdale PA. Transvaginal paravaginal repair: a useful adjunctive procedure in pelvic relaxation surgery. *J Pelvic Surg* 2000; 6:11–15.
10. Young SB, Daman JJ, Bony LG. Vaginal paravaginal repair: one-year outcomes. *Am J Obstet Gynecol* 2001; 185:1360–1367.
11. Mallipeddi PK, Steele AC, Kohli N, Karram MM. Anatomic and functional outcome of vaginal paravaginal repair in the correction of anterior vaginal wall prolapse. *Int Urogynecol J* 2001; 12:83–88.
12. Colombo M, Milani R, Vitobello D. A randomized comparison of Burch colposuspension and abdominal paravaginal defect repair for female stress urinary incontinence. *Am J Obstet Gynecol* 1996; 175:78–84.
13. Nguyen JK. Current concepts in the diagnosis and surgical repair of anterior vaginal prolapse due to paravaginal defects. *Obstet Gynecol Surv* 2001; 56:239–246.
14. Ostrzenski A. Genuine stress urinary incontinence in women: new laparoscopic paravaginal reconstruction. *J Reprod Med* 1998; 43:466–482.
15. Speights SE, Moore RD, Miklos JR. Frequency of lower urinary tract injury at laparoscopic Burch and paravaginal repair. *J Am Assoc Gynecol Laparosc* 2000; 7(4):515–518.