

Do we need new surgical techniques to repair vesico-vaginal fistulas?

João Paulo Zambon · Nelson S. S. Batezini ·
Eduardo R. S. Pinto · Milton Skaff · Marcia E. Girotti ·
Fernando G. Almeida

Received: 29 May 2009 / Accepted: 27 October 2009 / Published online: 1 December 2009
© The International Urogynecological Association 2009

Abstract

Introduction and hypothesis The urogenital fistula is a devastating condition for women. Despite advances in medical care, the vesicovaginal fistula continues to be a distressful problem. Complex vesicovaginal fistulae repair may need tissue interposition. It can be achieved by vaginal or abdominal approach and depends on the surgeon's experience and local factors like size, location, and previous radiotherapy. The aim of this study was to demonstrate that using traditional approaches is possible and reasonable to treat any sort of vesicovaginal fistula.

Methods Between January 2004 and August 2007, we treated 23 patients with complex urogenital fistulae. Of those with concomitant ureteral fistula requiring re-implantation or bladder augmentation, the vaginal approach was the first choice in 17 and abdominal approach in six. Patients were clinically evaluated at 1, 4, and 12 weeks postoperatively, then every 3 months in the first year.

Results Seventeen women were treated by vaginal approach and six patients were treated by abdominal approach. Hysterectomy was the major etiology (73.9%). Ten patients (43.5%) had at least one previous abdominal surgery for fistulae repair without success before. In those patients with abdominal approach, the hospitalization was longer than vaginal approach (80.5+/-6 h versus 48+/-3 h). In both, there were no major intraoperative or postoperative complications; 13% developed urgency and 4% developed

stress urinary incontinence. No patients have recurrence of fistulae (success rate 100%).

Conclusions Complex vesicovaginal fistulas are a big challenge for the urologist, and there is no gold standard surgical approach. The majority of complex vaginal fistula can be successfully managed by vaginal repair. As the vaginal approach is a minimally invasive procedure with low costs, easy learning curve, and high cure rates, new approaches must be carefully evaluated before being suggested as an alternative.

Keywords Vesicovaginal fistula · Vaginal approach · O' Connor technique

Abbreviations

VVF	Vesicovaginal fistula
VCUG	Voiding cystourethrography
IVU	Intravenous urography
USG	Ultrasonography

Introduction

The urogenital fistula is a devastating condition and it is part of the history of mankind. It has been described since 2050 BC as a large vesicovaginal fistula and laceration of the perineum, which is most likely due to birth trauma [1]. Despite the advances in medical care, the vesico-vaginal fistula (VVF) continues to be a distressful problem particularly in some poor and undeveloped countries that do not have an adequate obstetric assistance. Nonetheless, urogenital fistula is a worldwide problem even in wealthy countries where it is mainly related to hysterectomy [2].

J. P. Zambon (✉) · N. S. S. Batezini · E. R. S. Pinto · M. Skaff ·
M. E. Girotti · F. G. Almeida
Division of Urology, Female Urology,
Federal University of São Paulo, UNIFESP,
Napoléão de Barros, 715,
04023900 São Paulo, Brazil
e-mail: jp-zambon@uol.com.br

A small vesico-vaginal fistula that is without infection, has a good surrounding tissue, and without ureteral involvement, radiotherapy, and previous surgery is successfully handled by vaginal or abdominal approach or can be treated by indwelling catheter or fulguration of fistulous orifice [3, 4]. On the other hand, complex fistulas are a big challenge, and the first surgery is usually the best time to repair the problem.

Complex vesicovaginal fistulae repair may need tissue interposition like peritoneum, Martius flap, omentum, etc. It can be proceeded through with vaginal or abdominal approach and depends on the surgeon's experience and local factors like, size, location, and previous radiotherapy.

Recently, several reports have been designed supporting new procedures to vesico-vaginal fistula repair [5, 6]. New procedures are justified when it is easily reproducible, similar, or more effective than previous approaches providing better surgical outcomes with early patient recovery and lower costs. Traditionally, VVF repair has been described by vaginal or abdominal approach with more than 90% cure rates [7]. The vaginal approach is minimally invasive with short-term hospitalization, lower costs, and good results [7]. Since the vaginal approach allows high cure rate, short recovery, and relative lower costs and does not require any sophisticated material, why should we perform new expensive approaches such as robotic, laparoscopic, new flaps, etc.? Would it not be better to focus and provide better training on vaginal approach?

The aim of this study is to demonstrate that using traditional approaches are possible and reasonable to treat any sort of vesico-vaginal fistula. We present a series of patients with complex vesico-vaginal fistulae to demonstrate that it is possible to reconstruct the urogenital tract with good results using "old" procedures.

Material and methods

We retrospectively evaluated 22 patients with complex urogenital fistulae treated at our institution between January 2004 and August 2007. All patients were evaluated by medical history, physical examination (including bladder filling with methylene blue to demonstrate the fistula tract), urinalysis, voiding cystourethrography, intravenous urography (IVU), and cystoscopy. When the IVU was not conclusive regarding the ureteral integrity, it was evaluated by means of a retrograde ureterography immediately before the surgery. The inclusion criteria were: fistulae size greater than 2 cm, previous history of radiotherapy, VVF associated with ureteral fistulae, and infection or laceration at the fistulae site.

The vaginal approach was the first choice for all patients, with the exception of those with concomitant ureteral fistula

requiring re-implantation or bladder augmentation. In those situations, surgery was performed by abdominal or combined approach. We prefer early surgical approach of the fistula except in those patients with infection in the fistula site. In this situation, patients receive antibiotics (ciprofloxacin) until the tissue quality improves. Post-operatively, all patients received antibiotics (ciprofloxacin) for 1 week and the indwelling urethral catheter was maintained for 3 weeks. In those women requiring ureteral re-implantation, a ureteral stent for 4 weeks was used.

Patients were clinically evaluated at 1, 4, and 12 weeks postoperatively; then every 3 months in the first year. After removing the urethral catheter, all patients were evaluated by ultrasonography and urinalysis within 3, 6, 9, and 12 months. Patients who underwent ureteral re-implantation were evaluated with additional intravenous urography within 3 and 6 months. Success rate was defined as complete resolution of the fistulae with patient completely dry.

Vaginal approach was carried out as described by Raz S [8]. Patient was operated in dorsal lithotomic position. A 16-French urethral Foley catheter was used to drain the bladder. Routinely, we do not use suprapubic catheter. Fistula catheterization was performed in all patients with the 12-French Foley catheter depending on the fistula size. Fistulous orifice was carefully surrounded with delicate dissection. Two vaginal flaps, proximal and distal to the fistula, were created to allow a four-layer repair as previously described [8]. The first layer was created including fistulous orifice edges (Fig. 1). The second layer was created using the perivesical fascia. After closure of the second layer, the presence of leakage by filling the bladder was evaluated with 300 cc of saline dyed with blue methyl. To create a third layer, a peritoneal flap was advanced from the vaginal dome (Fig. 2). The fourth layer was created by a normal vaginal mucosa covering the

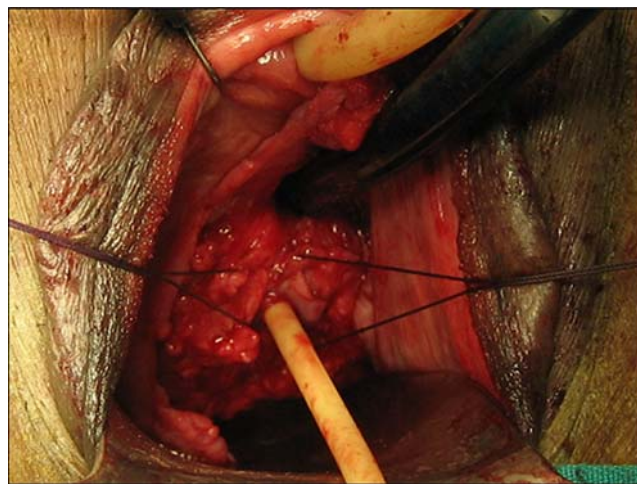


Fig. 1 Horizontal sutures: first layer, closing the fistula tract

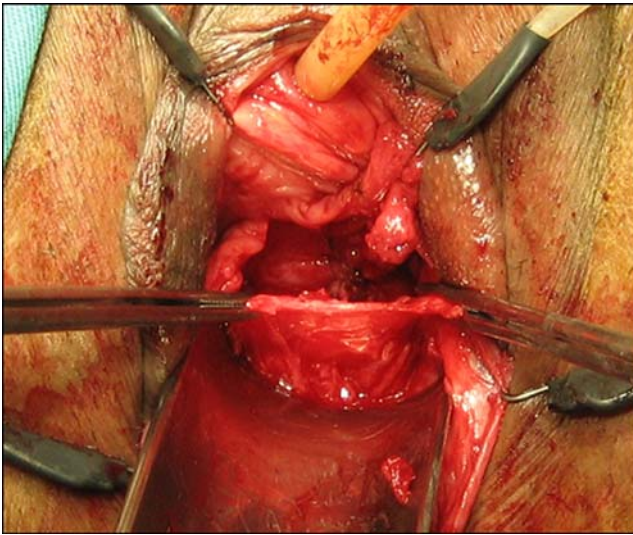


Fig. 2 Longitudinal sutures: second layer, covering the fistula tract

fistula site (Fig. 3). The sutures were placed in a such way that it avoids the suture line interposition (Figs. 2, 3, 4). We avoid using electrocautery, and the repair was made using absorbable 3.0 Vycril sutures.

Abdominal approach was carried out based on the O' Connor technique [9]. Patient was operated in horizontal dorsal position under general anesthesia. Access to the peritoneal cavity is done through an infra-umbilical incision, and the bladder is bivalved to expose the fistulous orifice (Fig. 4). We close the anterior vaginal wall with Vycril 2.0. The omentum or the peritoneal flap was inserted between the vagina and the bladder wall. The bladder wall was closed in two layers: mucosa and muscle with 3.0 and 2.0 Vycril sutures, respectively. Routinely, we do not use suprapubic catheter.

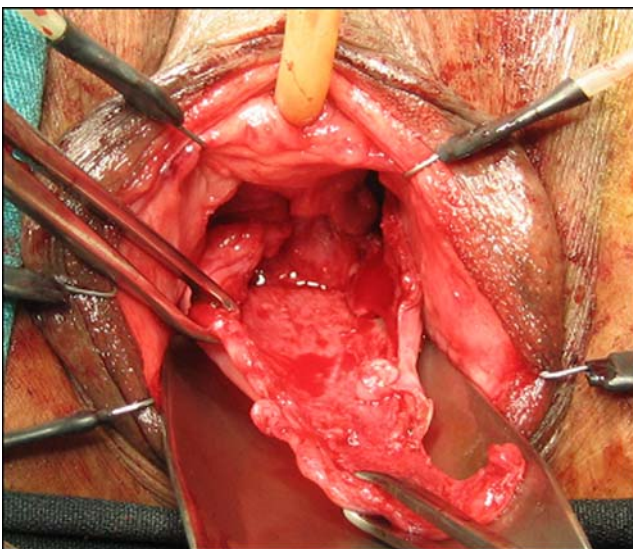


Fig. 3 Vaginal flap preparation: fourth layer, covering the fistula tract

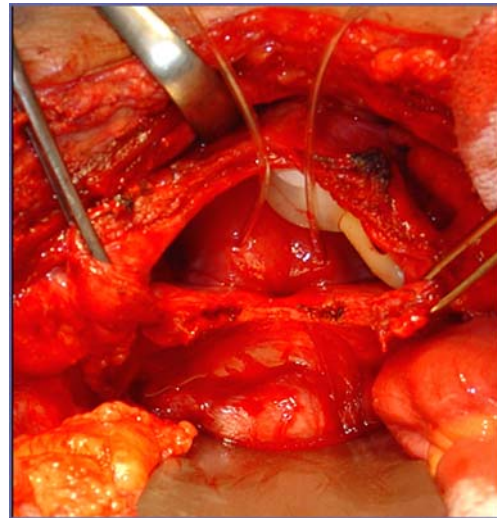


Fig. 4 Bivalving the bladder to abdominal fistula repair (O' Connor technique)

The post-operative analgesia was made with common analgesics, and ciprofloxacin was maintained for 7 days after the surgery.

Results

Out of the 22 patients, 16 women were treated by vaginal approach and six patients were treated by abdominal approach. The demographics are presented in Table 1. Hysterectomy was the major etiology, being responsible for 72.7% of all cases. Nine patients (41%) had at least one previous abdominal surgery for fistulae repair, without success, before being referred to our service. Out of them, three women had two previous interventions without success.

The vaginal approach allowed early hospital discharge. There were no major intraoperative or early postoperative complications such as bleeding, blood transfusion, or infection. The main reason for the longest hospitalization in those patients with abdominal approach was related to recovering from paralyzed ileum and pain. Dyspareunia occurred after 3 months only in women who submitted to vaginal approach. In these patients, vaginal length was short. All patients had tissue interposition (either peritoneal, omentum, or Martius flap). Table 2 shows the characteristics of the fistulae and the post-operative outcomes.

Discussion

Vesicovaginal fistula has been a medical and social problem for patients, and it remains a surgical challenge especially when it requires re-operation, presents a large size, involves

Table 1 Patient's demographics according to repair approach

	Abdominal (n=6)	Vaginal (n=16)
Mean age (years)	51.3±4	46.2±7
Etiology		
Hysterectomy	3 (50%)	13 (81.25%)
Sling	0	1 (6.25%)
Vaginal delivery	1(16.6%)	2 (12.50%)
Cesarean	1 (16.6%)	0
Radiotherapy	1 (16.6%)	0
Patients with previous surgical procedure failure	3 (50%)	6 (37.5%)
Mean time between fistula development and final treatment (months)	11.1±3	12.1±2

ureter, and is associated with radiotherapy. In this paper, we describe our experience with complex urogenital fistulas.

The obstetric fistula is frequently associated with ischemic tissue, producing large urogenital communication which increases the repair challenge. It is a commonplace to state that "the main fistula etiology in developed countries is the obstetric trauma" [10, 11]. This description is frail and should be amended to point to the real problem which is the lack of adequate obstetric support during parturition. Countries with good obstetric assistance have a decrease in obstetric fistula and the main etiological factor is iatrogenic gynecological procedure. In this case, urogenital fistulas can be developed in 1-6 weeks after gynecological procedure [6, 7]. In our series, 72% of patients had been submitted to hysterectomy.

When planning vesicovaginal fistula repair, it is important to evaluate the local conditions. Early surgical approach is recommended by many authors if local conditions are adequate [7, 12, 13]. In our series, the time between the fistula development and final repair was about a year, reflecting a great patient distress, in particular, for

those needing re-operation. Recurrent fistulas can present within 3 months after primary repair [12, 13]. In our series, we found that the mean time to fistula recurrence (n=9) was 25 days (ranging 7–60 days), and 41% of the patients had at least one attempt to repair the fistula without success. It is important to point it out because it demonstrates the necessity to offer better training in fistula repair rather than create new approaches with expensive materials. The first surgery is the best moment to repair the fistula and it should be carefully planned and performed to reach the highest cure rate.

There are some golden rules on vesico-vaginal fistulas repair, which seems to increase the success rate. We believe that VVF should preferably be close with multiple layers without tension, and complex fistula should be corrected using tissue interposition. The great omentum is commonly used when the abdominal approach is chosen. When vaginal approach is chosen, there are a lot of options such as Martius flap, peritoneum, gluteal flap, etc. Martius flap is a good option when the VVF is located under the trigone, but the graft choice depends on the surgeon's experience.

Table 2 Characteristics of the fistula and post-operative outcomes

	Abdominal (n=6)	Vaginal (n=16)
Mean size (cm)	2.5+/-0.6	3.2±0.5
Above the trigone	6 (100%)	13 (81.25%)
Hospital discharge (mean hours)	80.5±6	48±3
Tissue interposition		
Peritoneum	2 (33.3%)	13 (81.25%)
Martius flap	00	3 (18.75%)
Omentum	4 (66.6%)	0
Ureteral re-implantation	2 (33.3%)	0
Ileal bladder augmentation	1 (radiotherapy; 16.6%)	0
Urgency	1 (16.6%)	2 (12.5%)
Dyspareunia	0	4 (25%)
Stress urinary incontinence	1(16.6%)	0
Success rate	100%	100%

Eilber reported a 10-year experience in the treatment of vesico-vaginal fistula with tissue interposition and success rate with peritoneum flap or Martius flap ranging from 95–97% [7, 14]. In the present series, the complexity of the fistulas required tissue interposition (peritoneum, omentum, or Martius flap) in all cases. Despite complexity, the majority of patients were treated by vaginal approach. Selecting vaginal or abdominal approach depends on several factors such as the surgeon's experience, fistula size and location, ureteral involvement, concomitant pathological conditions, local vaginal conditions, and accessible tissue interposition. Vaginal approach is our first choice to repair vesico-vaginal fistula, because it is a faster minimally invasive procedure with low morbidity, minimal blood loss, and early hospital discharge. Additionally, it avoids laparotomy and cystotomy.

In the same way, the abdominal approach such as the O' Connor procedure has a high cure rate, and patients with poor fistula exposure due to vaginal stenosis, post-radiotherapy, fibrotic vaginal tissue, and poor surrounding tissue that could be used to reconstruction or needing ureteral re-implantation, may be better managed by abdominal surgery [15]. In a patient that had previous radiotherapy and presented intense vaginal stenosis with poor vaginal tissue, although the vaginal approach could be feasible, we prefer to perform an abdominal approach.

The majority of patients with vesico-vaginal fistula want to preserve their sexual function after the surgery. Surgeons performing vaginal fistula repair need to preserve the vaginal length and maintain an adequate diameter with complaint tissue. Elkins et al. reported 50% of ginatresia after correction of obstetric fistula larger than 4.0 cm. In these cases, the fistula repair reduces the vaginal length and prevents future sexual activities [11]. In our series, 25% of the patients underwent vaginal fistula repair present some degree of dyspareunia postoperatively.

Despite of excellent results obtained with traditional techniques, some authors introduce the laparoscopic approach to decrease the morbidity of open surgery while maintaining high success rate. The first laparoscopic fistula repair was reported in 1994 [16]. **Although the laparoscopic approach, in expert hands, may provide high success rate, it is not widely practiced due to the costs and considerable learning curve imposed by extracorporeal freehand suturing [16]. Miklos reported the first successful laparoscopic repair of recurrent VVF [17], but there is a lack of studies regarding laparoscopic repair of complex VVF.**

The first robotic-assisted laparoscopic repair of VVF was described by Melamud et al. from the University of California-Irvine [18]. The robotic assistance has the potential benefits to laparoscopic surgery while maintaining the advantages of minimally invasive procedure. Proponents of laparoscopic-robotic surgery explain that the

robotic vision facilitates direct access to the fistulous site, requiring minimal posterior cystotomy for dissecting out the fistula. The smaller cystotomy and need for lesser mobilization helped in avoiding the need to place a suprapubic cystostomy [19]. The main problem with robotic surgery worldwide is the same when faced with laparoscopic procedure, which are the costs and extensive training. In our study, 73% of the patients were treated by vaginal repair, which is as minimally invasive as any laparoscopic or robotic procedure. Since the vaginal fistula repair allows a minimally invasive procedure with low cost, easy learning curve, fast recovery, and hospital discharge with high cure rates, we believe that it is not justifiable to spend time and money on laparoscopic or robotic surgery aiming to treat vesico-vaginal fistulae.

Conclusions

Complex vesicovaginal fistulas are a big challenge for the urologist and there is no gold standard surgical approach. The surgeon's experience with surgical technique and anatomy seems to be the main factor for treatment success. The evaluation of fistulas must be done with care to prevent recurrence. The majority of complex vaginal fistula can be successfully management by vaginal repair. However, some situations may require abdominal or even combined intervention. As the vaginal approach is a minimally invasive procedure with low costs, easy learning curve, and high cure rates, new approaches must be carefully evaluated before being suggested as an alternative.

Conflicts of interest None

References

1. Derry DE (1935) Note on five pelves of women of the eleventh dynasty in Egypt. *J Obstet Gynaecol Br Emp* 42:490–493
2. Mattingly RF, Thompson JD (1985) *Te Linde's operative gynecology*. J.B. Lippincott, Philadelphia, Philadelphia
3. Davits RJ, Miranda SI (1991) Conservative treatment of vesico-vaginal fistulas by bladder drainage alone. *Br J Urol* 68:155–156
4. Stovski MD, Ignatoff JM, Blum MD, Nanninga JB, O'Connor VJ, Kursh ED (1994) Use of electrocoagulation in the treatment of vesicovaginal fistulas. *J Urol* 152:1443–1444
5. Hemal AK, Kolla SB, Wandhwa P (2008) Robotic reconstruction for recent supra-trigonal vesicovaginal fistulas. *J Urol* 180:981–985
6. Cohen BL, Gousse AE (2007) Current techniques or vesicovaginal fistulas repair: surgical pearls to optimize cure rate. *Curr Urol Rep* 8:413–418
7. Eilber KS, Kavalier E, Rodríguez LV, Rosenblum N, Raz S (2003) Ten-year experience with transvaginal vesicovaginal fistula repair using tissue interposition. *J Urol* 169:1033–1036

8. Raz S (2002) Atlas of transvaginal surgery. WB Saunders, Philadelphia
9. O'Connor VJ, Sokol JK, Bulkley GJ, Nanninga JB (1973) Suprapubic closure of vesicovaginal fistula. *J Urol* 109:51–54
10. Creanga AA, Ahmed S, Genadry RR, Stanton C (2007) Prevention and treatment of obstetric fistula: identifying research needs and public health priorities. *Int J Gynecol and Obstet* 99:141–154
11. Elkins TE (1994) Surgery for the obstetric vesicovaginal fistula: a review of 100 operation in 82 patients. *Am J Obstet Gynecol* 170:1118–1120
12. Blandy JP, Badenoch DF, Fowler CG, Jenkins BJ, Thomas NW (1991) Early repair of iatrogenic injury to the ureter or bladder after gynecological surgery. *J Urol* 146:761–765
13. Blaivas JG, Heritz DM, Romanzi LJ (1995) Early versus late repair of vesicovaginal fistulas: vaginal and abdominal approaches. *J Urol* 153:1110–1112
14. Eilber KS, Rosenblum N, Rodriguez LV (2005) Female urology, urogynecology and voiding dysfunction. Marcel Dekker, New York
15. Nesrallah LJ, Srougi M, Gittes RF (1999) The O'Connor technique: the gold standard for supratrigonal vesicovaginal fistulas repair. *J Urol* 165:566–568
16. Nezhat CH, Nezhat F, Nezhat C, Rottenberg H (1994) Laparoscopic repair of vesicovaginal fistula: a case report. *Obstet Gynecol* 83:899
17. Myklos JR, Sobolewski C, Lucente VR (1999) Laparoscopic management of recurrent vesicovaginal fistula. *Int Urogynecol J Pelvic Floor Dysfunct* 10:116
18. Melamud O, Eichel L, Turbow B, Shanberg A (2005) Laparoscopic vesicovaginal fistula repair with robotic reconstruction. *Urology* 65:163
19. Sundaram BM, Kalidasan G, Hemal AK (2006) Robotic repair of vesicovaginal fistula: case series of 5 patients. *Urology* 67:970