

A laparoscopic view of the pelvic region during a surgical procedure. The image shows the uterus and surrounding structures, with several white sutures and surgical instruments visible. The background is a reddish-brown color, likely due to the surgical field's lighting and the presence of blood vessels.

# *Laparoscopic Paravaginal Repair and Burch Urethropexy*

**ROBERT D MOORE**  
**JOHN R MIKLOS, NEERAJ KOHLI**

**Chapter Twelve**

## INTRODUCTION

Since the introduction of the retropubic urethral suspension in 1910, over 100 different surgical techniques for the treatment of genuine stress urinary incontinence (GSUI) have been described.<sup>1</sup> Many have been modifications of original procedures in an attempt to improve clinical outcome, shorten operative time, and reduce surgical morbidity. Despite the number of surgical procedures developed each year, the Burch colposuspension and pubovaginal sling operations have remained the mainstay of surgical correction for GSUI because of their high long-term cure rates. However, these procedures do not address the concurrent anterior vaginal wall prolapse often associated with GSUI secondary to urethral hypermobility. We present a laparoscopic approach to anterior vaginal wall reconstruction using the paravaginal repair and Burch colposuspension for treatment of cystocele and stress urinary incontinence, respectively, resulting from lateral vaginal wall support defects.

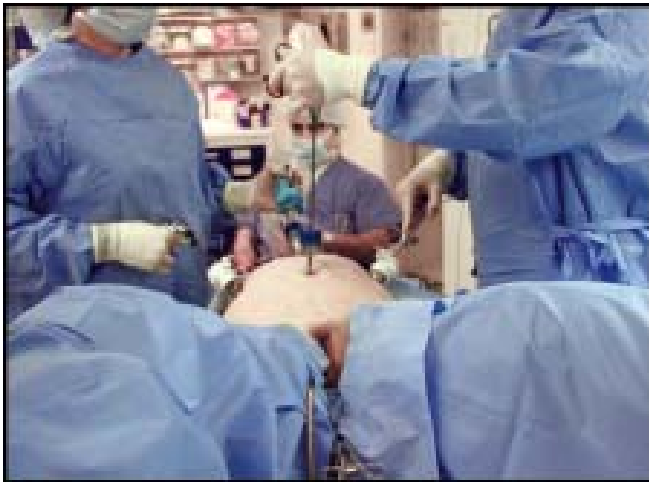Emphasizing the principles of minimally invasive surgery, the laparoscopic approach has been successfully adopted for many procedures that previously relied on an abdominal or transvaginal route. First described in 1991, the laparoscopic retropubic colposuspension has rapidly gained popularity because of its many reported advantages, including improved visualization, shorter hospital stay, faster recovery, and decreased blood loss.<sup>2</sup>

Laparoscopy should be considered only as a mode of abdominal access and not a change in the operative technique. Ideally the indications for a laparoscopic approach to retropubic colposuspension should be the same as an open (laparotomy) approach. This would include patients with GSUI and urethral hypermobility. The authors believe the laparoscopic Burch colposuspension can be substituted for an open Burch colposuspension in the majority of cases. Factors that might influence this decision include any history of previous pelvic or anti-incontinence surgery, the patient's age and weight, the need for concomitant surgery, contraindications to general anesthesia, and the surgeon's experience. The surgeon's decision to proceed with a laparoscopic approach should be based on an objective clinical assessment of the patient as well as the surgeon's own surgical skills. Loss of the lateral

vaginal attachment to the pelvic sidewall is called a paravaginal defect and usually results in a cysto-urethrocele and urethral hypermobility. If the patient demonstrates a cystocele secondary to a paravaginal defect diagnosed either pre- or intraoperatively, a paravaginal defect repair should be performed before the colposuspension. This approach combines the paravaginal repair with Burch colposuspension for treatment of anterior vaginal prolapse secondary to paravaginal defects and stress urine incontinence secondary to urethral hypermobility.<sup>3-5</sup> The paravaginal defect repair also places the anterior vaginal wall in its correct anatomic position, i.e. at the level of the arcus tendineus fascia pelvi prior to the Burch sutures being placed. This helps minimize the chance of overcorrection of the bladder neck with the Burch sutures because the paravaginal repair limits how much the Burch sutures can be tightened and only allows the bladder neck to be elevated approximately 1-2 cm above the level of the base of the bladder. This adjustment and limitation helps reduce the risk of postoperative voiding dysfunction.

We recommend that all patients have a modified bowel preparation consisting of a full liquid diet 48 hours before scheduled surgery and a clear liquid diet and one bottle of magnesium citrate 24 hours before surgery. This regimen appears to improve visualization of the operative field by bowel decompression and reduces that chance of contamination in case of accidental bowel injury. A single dose of prophylactic intravenous antibiotics is administered 30 minutes before surgery. Antiembolic compression stockings are routinely used. The patient is intubated, given general anesthesia, and placed in a dorsal lithotomy position with both arms tucked to her side. A 16 F 3-way Foley catheter with a 5 mL balloon tip is inserted into the bladder and attached to continuous drainage (Fig. 12.1).

Since Vancaillie and Schuessler<sup>2</sup> published the first laparoscopic colposuspension case series in 1991, many other investigators have reported their experience. Review of the literature reveals a lack of uniformity in surgical technique and surgical materials used for colposuspension. This lack of standardization is also noted with the conventional open (laparotomy) technique. Because of this lack of standardization and the steep learning curve associated with laparoscopic suturing, surgeons have



**Fig. 12.1:** Positioning. The patient is placed in dorsal lithotomy position in adjustable Allen stirrups. A 3-way Foley catheter is placed to be able to retrograde fill the bladder. The surgeon stands on the patient's left side and the assistant on the right side

attempted to develop faster and easier ways of performing a laparoscopic Burch colposuspension. These modifications have included the use of stapling devices, bone anchors, synthetic mesh, and fibrin glue.<sup>6-8</sup> However, we believe the laparoscopic approach should be identical with the open technique to allow comparative studies as well as to ensure the patient is receiving an identical procedure utilizing either approach. When conventional surgical technique is described and utilized, cure rates have been shown to be identical via a laparoscopic or open approach.<sup>9-14</sup> Advantages of the laparoscopic approach are improved visualization, decreased blood loss, decreased bladder/ureteral injuries and magnification of other pelvic floor defects that need to be repaired.<sup>15-17</sup> Other advantages include less postoperative pain, shorter hospital stays and shorter recovery time with faster return to a better quality of life.

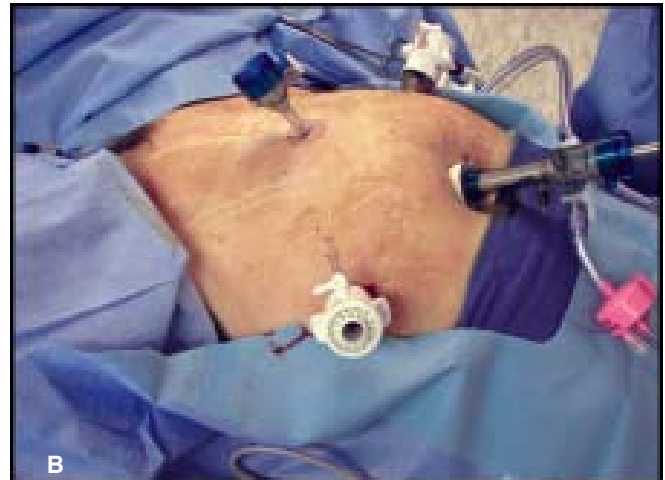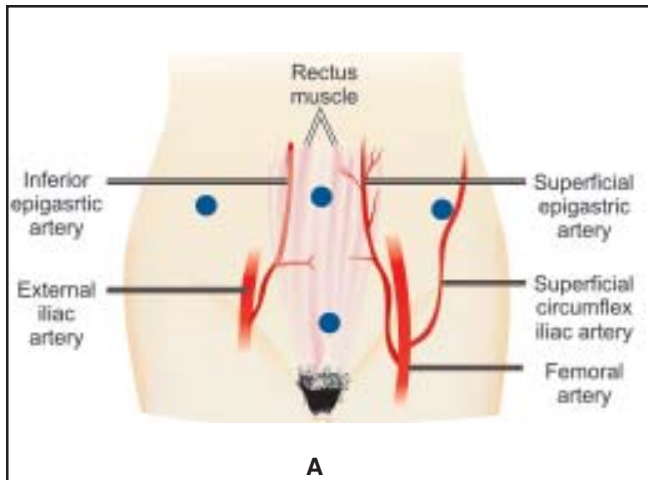
The space of retzius is one of the most difficult areas to suture laparoscopically secondary to limited space and the angles required to place and retrieve sutures. We utilize one port to do all of our laparoscopic suturing and the surgeon is the only one passing and retrieving needles. Some authors recommend either using their assistant to load or retrieve needles or the surgeon changes sides of the table to suture on the patient's contralateral side. We feel this is not

necessary, nor is it efficient. Utilizing proper angles and needle placement, as well as utilizing the vaginal hand to elevate and manipulate the anterior vaginal wall, the surgeon can complete all suturing from one side of the table and utilize the assistant to hold the camera and retract only. We feel this helps improve efficiency, safety and optimizes the economy of motion of the procedure. There is no need for the surgeon or the assistant to change sides of the table.

### Equipments and Sutures

Many different types of sutures and instruments have been described for use in laparoscopic paravaginal repair and Burch colposuspension. We feel that permanent sutures should be utilized in pelvic floor repairs and therefore utilize permanent sutures in laparoscopic Burch/PVR. Our suture of choice for pelvic reconstructive surgery is 2-0 Ethibond (Ethicon) on a SH needle, which is a braided permanent suture. To be able to tie extracorporeal knots when suturing in the space of retzius, it necessary to have a minimal suture length of 48 inches, therefore some sutures may need to be special ordered to obtain this minimal length. Since there is a limitation of space retropublically, we have found the ideal size of needle utilized should be no larger than an SH needle. CT-1 needles have been utilized, however we find these needles too large to manipulate in the space of retzius and feel there is more chance of injury to vascular and visceral structures. We utilize Gore-Tex permanent sutures on a CV-1 taper cut needle for the Burch portion of the procedure secondary to taking two passes through the pubocervical fascia. A double-pass allows us to get an adequate purchase of vaginal tissue and the nature of the Gore-Tex suture allows the suture to slide very easily through the tissue, even with a double-bite. Braided sutures such as Ethibond or Vicryl do not slide through the tissue like this and each throw through the tissue has to be taken separately which increases operative time. In paravaginal repair, only one pass is taken through the vagina and sidewall and therefore Gore-Tex (which is more expensive than Ethibond) is not necessary.

As stated above, the surgeon completes all suturing, retrieving of needles and knot-tying from one port on the patient's left side (if right handed). The assistant stands on the patient's right side and holds

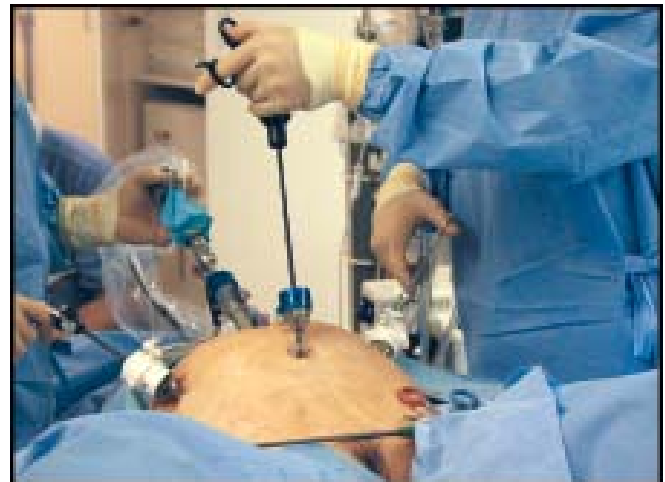

**Figs 12.2A and B:** Port Placement. Taut Adept ports are used throughout the procedure. A 10 mm balloon trocar is used in the umbilicus, as we complete open approach in all patients for safe access into the abdomen. Three other ports are placed, a 5/10 mm port in the left paramedian region which is used for all suturing, and two 5 mm ports placed in the suprapubic and right paramedian region. The suprapubic port is placed high, approximately 4 fingerbreadths above the pubic bone to be able to have access to the retropubic region

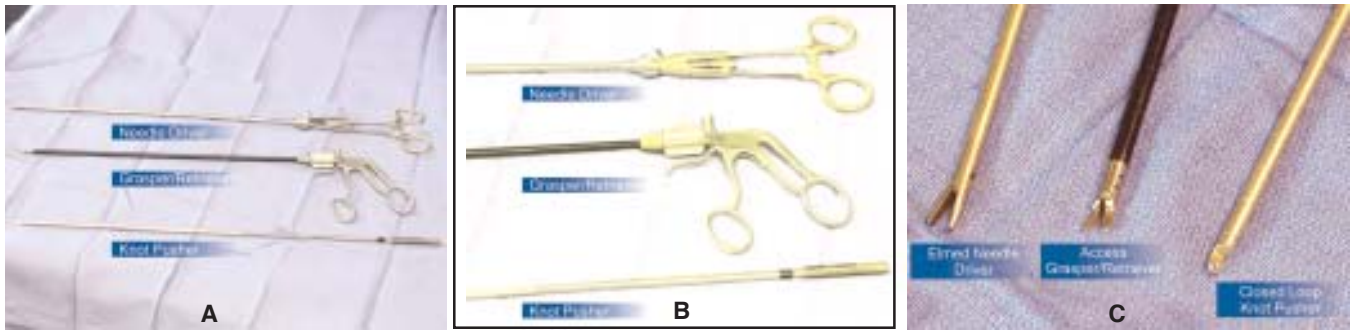
the camera with their left hand and uses their right hand to assist in the surgical field. The suturing port needs to a minimal of 10 mm to be able to accommodate passing the needle through the port. Secondary to multiple sutures being placed throughout a laparoscopic reconstructive procedure, it is not efficient to utilize other methods of needle placement into the abdominal cavity that may take several steps to try to utilize a smaller (i.e. 5 mm) port. We currently use the Adept (Taut) 5/10 mm port in the left lower quadrant that has a diaphragm designed to not leak gas when suturing and also allows up to a CT-1 needle to be passed easily in and out of the abdominal cavity. Two 5 mm ports are used as well. One is placed suprapubically that the surgeon utilizes with his left hand for a grasper to retrieve needles and the other is placed in the right lower quadrant that the assistant uses for retraction, suction/irrigation, etc. All sutures are thrown from the left to the right in the patient (Figs 12.2A and B and 12.3).

We utilize an Elmed needle driver for all of our laparoscopic suturing (Figs 12.4A to C). It is designed exactly like a traditional needle driver and also allows the needle to be placed with different angles and locked in these positions, which is important for suturing in the Space of Retzius. Self-righting needle drivers may be easier to use for beginners, however, they do not allow the needle to be at any other angle but 90 degrees, nor can the needle be leaned in or

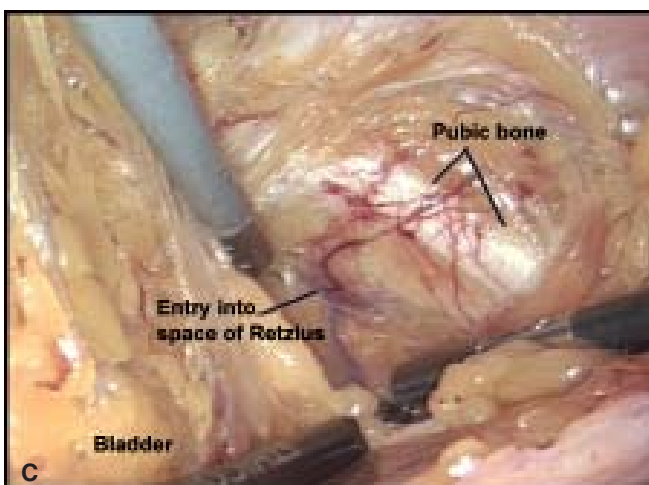
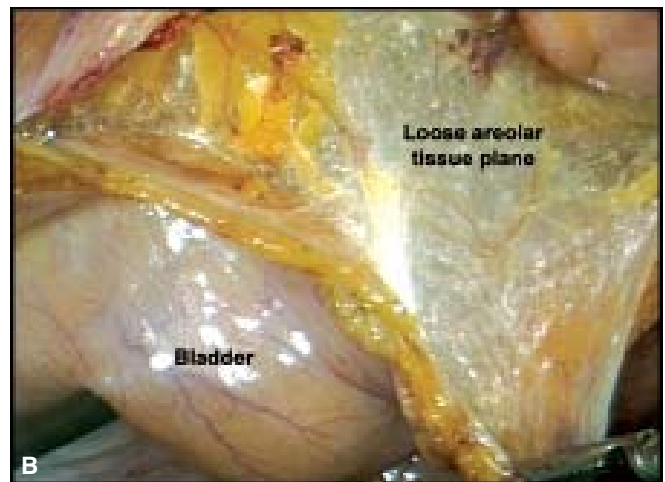
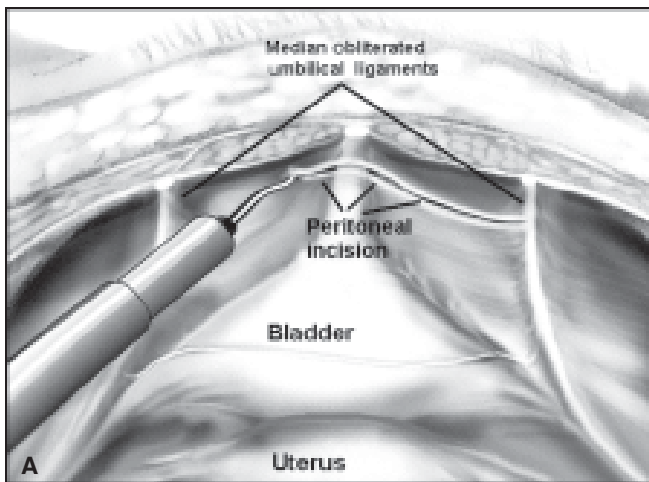
out, again limiting your suturing abilities. The surgeon also utilizes an Access needle driver through the suprapubic port, however, it is used as a retriever/grasper and not a driver. We have found



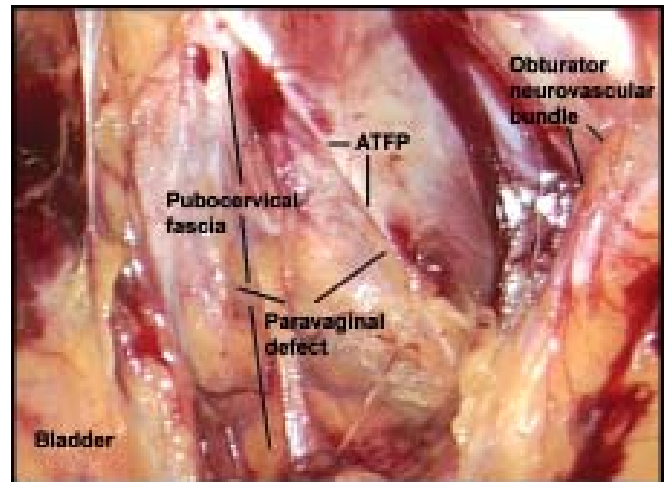
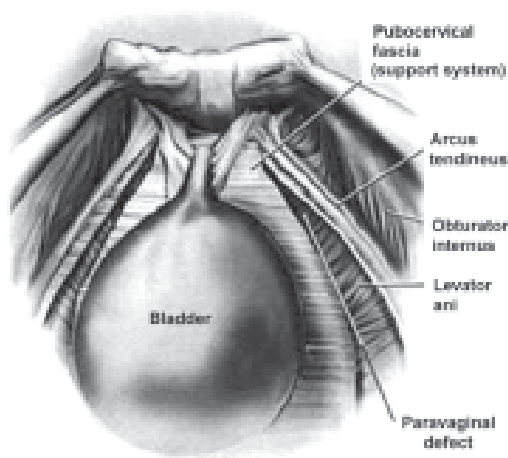
**Fig. 12.3:** Hand placement. The lateral ports are also placed up higher on the abdominal wall for easier access into the retropubic space and to be able to operate comfortably and ergonomically. The surgeon operates with both hands at all times. The left port is used to complete all suturing and the suprapubic port is used for grasping tissue and retrieving the needle. All knot tying is completed extracorporeally through the left paramedian port. The instrument used in the suprapubic port is held “backwards” which gives us much more range of motion with the instrument when rotating the wrist versus holding it the more “traditional” way



**Figs 12.4A to C:** Laparoscopic suturing instruments. The surgeon utilizes 3 instruments to suture. The needle driver is an Elmed needle driver, that is exactly the same as a traditional needle driver, however it is made longer for laparoscopic use. It is not self-righting as we need to place the needle at different angles at times when suturing and self-righting needle drivers do not allow you to do this. We utilize an access needle driver actually as our grasper and retriever as we find the jaws to be very precise to grasp as well as rotate fully and do not ratchet or lock down. The knot pusher is also manufactured by Access and is close-ended



**Figs 12.5A to C:** (A) A transperitoneal approach is utilized to complete the procedure, this allows access to the remainder of the pelvis and to complete other reconstructive procedures as necessary. The bladder is retrograde filled with 200-300cc of sterile water solution through a 3-way Foley catheter. This allows clear visualization of the superior border of the bladder edge, which in some cases is above the level of the superior pubic symphysis. A harmonic scalpel is utilized to gain entry into the retroperitoneal space. An incision is made in the peritoneum approximately 3 cm superior to the dome of the bladder between the obliterated umbilical ligaments which can be clearly visualized in most patients, (B) Staying medial (inside) to the ligaments protects the surgeon from injuring the inferior epigastric vessels which run lateral to the ligaments. Identification of loose areolar tissue (white cob-web type tissue) confirms a proper plane of dissection, (C) After the space of Retzius has been entered and the pubic ramus visualized, the bladder is drained in order to prevent injury. Separating the loose areolar and fatty layers using blunt dissection develops the retropubic space. Blunt dissection is continued until the retropubic anatomy is visualized



**Figs 12.6A and B:** Retropubic anatomy visualized after blunt dissection completed on patient's right side. A laparoscopic kitner (peanut) is used to gently clean off the pubocervical fascia. The pubic symphysis and bladder neck are identified in the midline and the obturator neurovascular bundle, Cooper's ligament and the arcus tendineus along the pelvic sidewall. Clearly visualized is the lateral margin of the detached pubocervical fascia and the broken edge of the white line, creating a paravaginal defect on this side.

The dissection is continued on the patient's left side and anatomy identified. The anterior vaginal wall and its point of lateral attachment from its origin at the pubic symphysis to its insertion at the ischial spine are identified

this to be an excellent needle retriever as it can be used as a grasper and has the advantage of slightly curved delicate jaws that can be rotated and does not lock down, therefore can also stabilize the needle in position in the tissue when necessary as well. We hold the Access "backwards" with our left hand, as this allows us almost 360° of motion with simple rotation of the left wrist. Sutures are tied extraportally with a closed loop Saye/Reddick knot-pusher. Extraportable knot tying is much faster and more efficient than intraportable knot tying, again decreasing overall operating time.

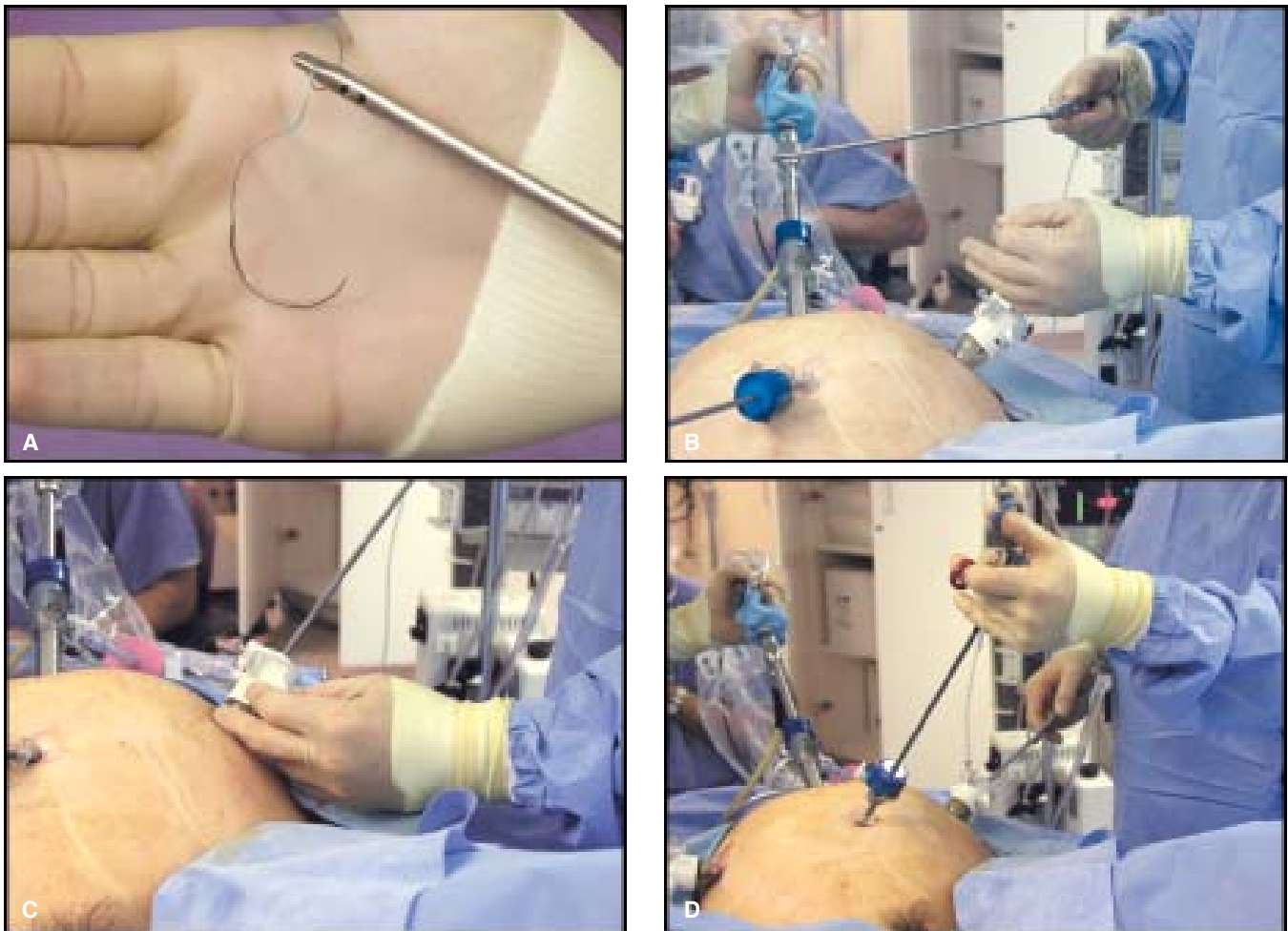
## POTENTIAL COMPLICATIONS AND INJURIES

### Lower Urinary Tract Injuries

The most common reported complication of Burch and Paravaginal repair is injury to the bladder and/or the ureters. Lower urinary tract injuries have been reported to be as high as 4 percent in open procedures.<sup>18,19</sup> We have shown a much lower rate of injury with a laparoscopic approach,<sup>17</sup> however other reports have reported injury rates as high as 6 percent<sup>20</sup> and therefore one must be prepared to handle these complications. Clearly injury to the lower urinary tract is higher when there has been previous surgery in the space of retzius such as

previous Burch/MMK or retropubic sling procedure as the space will have extensive scar tissue in it and therefore risk of injury to the bladder or vasculature is much higher. We recommend only advanced experienced laparoscopic surgeons attempt dissection and repair in these patients. Again patient selection and surgeon experience are key determinants in minimizing risk of injury in advanced laparoscopic surgery.

Cystotomy is the most common bladder injury encountered and typically occurs during dissection into the space of Retzius. We recommend using a 3-way Foley catheter to retrograde fill the bladder with 250 cc of fluid prior to beginning the dissection into the Space. Once the bladder is filled, the superior edge of the dome of the bladder is identified and the incision made between the obliterated umbilical ligaments approximately 3 cm above this. After making the initial incision through the peritoneum, blunt dissection is used to find the loose areolar tissue (cob-web like appearance) and then the dissection continued down to the pubic bone. Once the pubic bone is identified, the risk of bladder injury is minimal and therefore the bladder is emptied to have better visualization of the space. Blunt dissection is continued and then a laparoscopic Kittner is used to gently clean the fatty tissue off the pubocervical



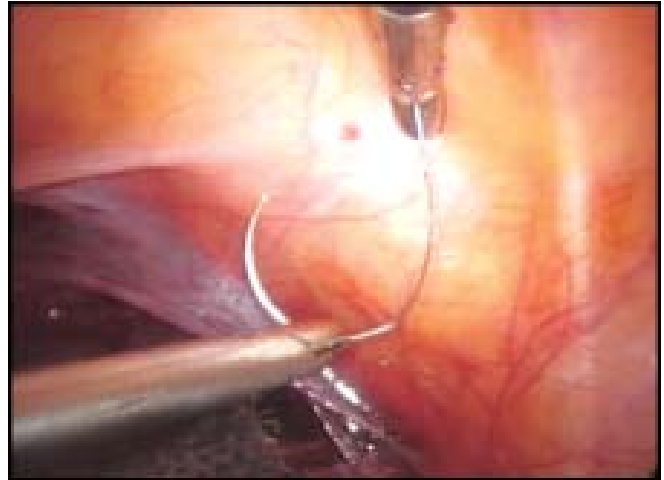
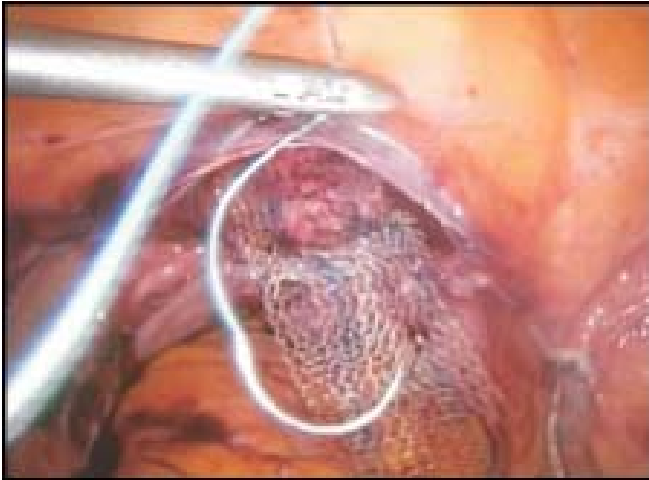
**Figs 12.7A to D:** Laparoscopic suturing technique. A 2-0 braided non-absorbable suture (Ethibond) on a SH needle is utilized for the paravaginal defect repair. The suture is grasped with the Elmed needle driver approximately 3 cm from the needle and is fed through the 5/10 mm Taut suturing port in the left paramedian region into the abdomen. The surgeon utilizes the Access needle driver in his left hand through the suprapubic port as a grasper/retriever during the suturing process (D). The assistant holds the camera and a grasper for retraction or suction and does not assist in any needle passage, retrieving, etc. The surgeon is self-sufficient and does all aspects of suturing from the left side with no assistance

fascia. A finger is placed in the vagina, to elevate the vagina up and the kittner (peanut) is then used to ensure the bladder is gently dissected medially off the lateral pubocervical fascia where sutures will be placed for the repair. As long as the “white” pubocervical fascia can be visualized the risk of suture placement in the bladder is minimal.

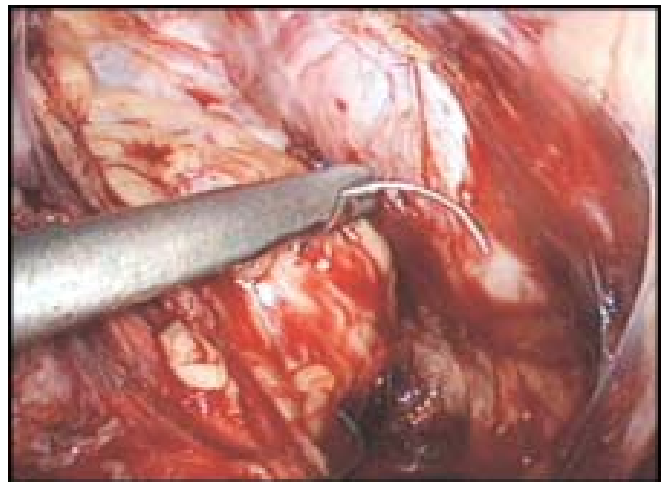
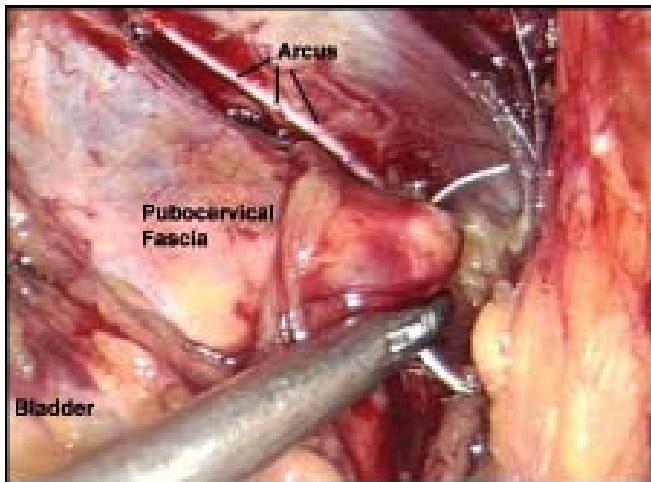
If cystostomy occurs, it typically is during dissection and is at the dome of the bladder, far away from the ureters and typically is a very simple repair. Cystoscopy should be completed to ensure the ureters are not involved or close enough to the injury

that the repair would compromise them. The cystostomy should be repaired laparoscopically with interrupted sutures of 3-0 vicryl in two layers. Cystoscopy should be completed after repair to ensure water tight closure and ureteral patency. If the repair is close to one of the ureters, a ureteral stent should be placed during repair to ensure patency and to protect the ureter. Postoperative drainage for 7 days with Foley catheter is recommended following repair.

Postoperative cystoscopy is recommended for all patients undergoing Burch and/or paravaginal repair



**Figs 12.8A and B:** Suture placement. Once in the abdomen, the surgeon regrasps the suture with the instrument in the suprapubic port with his left hand and allows the needle to dangle freely in the abdomen (A). The jaws of the grasper can then be rotated to place the needle in the proper position to be loaded in the needle driver in his right hand. The needle can also be gently laid on the sidewall to help in loading into a correct position as well (B)

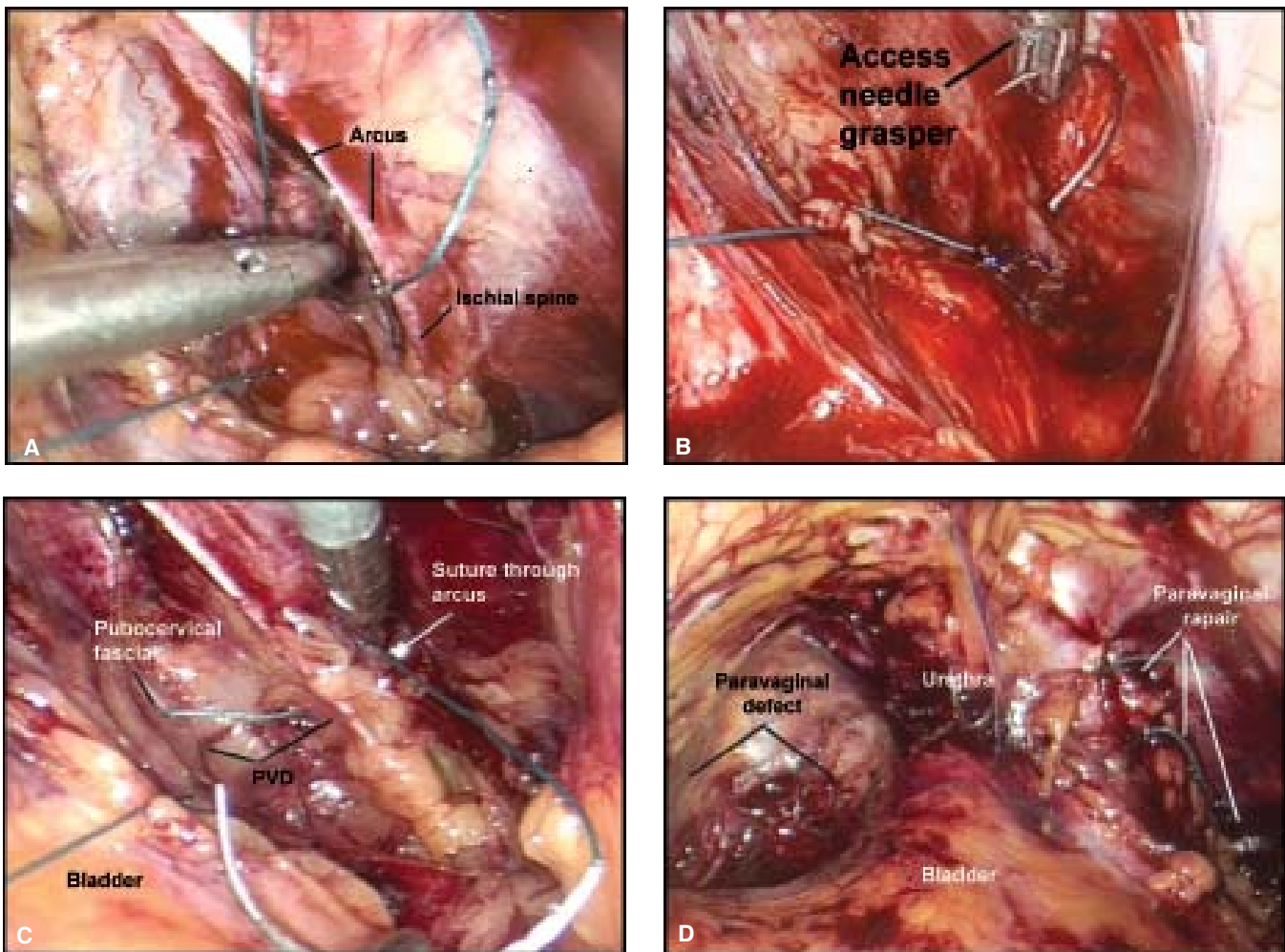


**Figs 12.9A and B:** Paravaginal defect repair, right side. The assistant lays an instrument across the bladder, opening the retropubic space for suturing. The surgeon places his left hand in the vagina and elevates the anterior vaginal wall up to place the first suture into the pubocervical fascia at the apex of the defect near the top of the vagina on the right side. The assistant retracts the bladder away from the pubocervical fascia and the surgeon then places the needle through the fascia (A). Maintaining the elevation of the vagina with his left index finger, the needle is then retrieved with the driver in his right hand, (B) and reset using both instruments if needed. Separate passes are always utilized for the vagina and the sidewall to ensure proper placement and adequate tissue bites

to ensure ureteral patency and that there is no injury to the bladder, or sutures in the bladder. An ampule (5 cc) of indigo carmine is given to the patient intravenously to ensure ureteral patency. If there is ureteral compromise, the sutures on that side must be removed. The most common suture that could cause ureteral obstruction is the highest paravaginal

suture that is placed near the ischial spine and this is the first suture that should be released. If ureteral patency is still compromised, the next suture that should be removed is the Burch suture at the bladder neck. If the ureter is still not patent then all sutures on that side should be removed and a number 5 or 6 ureteral stent passed to assure patency. The stent





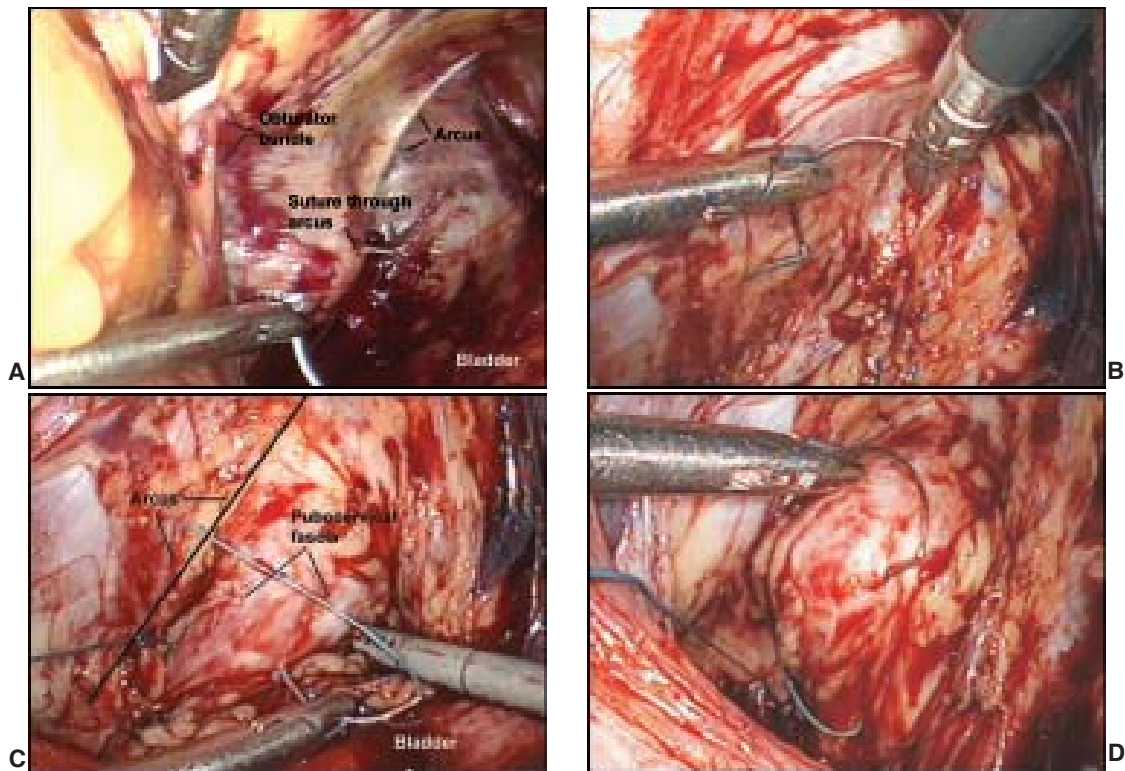
**Figs 12.10A to D:** Second needle pass, attachment to sidewall. Once the needle is reset, the surgeon then passes the needle through the ipsilateral obturator internus muscle and fascia around the arcus tendineus fascia at its origin 1-2 cm distal to the ischial spine (A). The assistant uses a grasper or retractor to keep the space open and extreme care must be used to identify and know the position of the obturator neurovascular bundle at all times. When placing sutures through the sidewall (on either side) the surgeon uses both hands, his right hand to drive the needle and his left hand with the Access grasper to retract if necessary and then retrieve the needle from the sidewall (B, C). The suture is then tied by the surgeon extracorporeally using the closed-loop knot pusher and 3-4 more sutures are placed with the same technique on this side for repair of the right sided defect (D).

should be left in place and the sutures replaced. As long as there is no evidence of ureteral injury (i.e. blue dye spilling into the space of Retzius), the stent can be removed immediately following the procedure. If a suture is seen penetrating the bladder on cystoscopy, it needs to be removed and replaced. There is no need for prolonged catheterization following removal of a suture from the bladder.

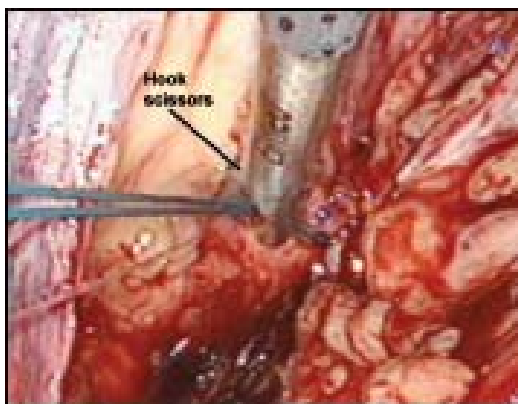
### Vascular Injuries

The most common and devastating vasculature injury that can occur in the space of Retzius would be to

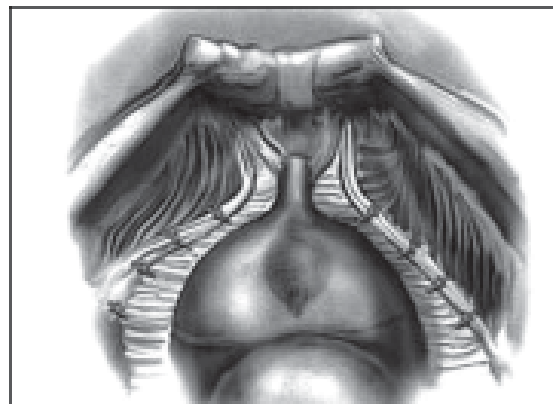
the obturator neurovascular bundle. This should be one of the first structures visualized when entering the space and the surgeon must be aware of its location at all times throughout the procedure. Typically, injury to this structure occurs with the shaft of the needle (i.e. the back of it) when trying to manipulate the needle in the Space. If injury occurs to the obturator bundle, brisk bleeding will be encountered. Suction irrigation must be utilized immediately to try to obtain visualization and ultimately hemostasis. We recommend utilizing 10 mm hemoclips to obtain hemostasis laparoscopically, however, the



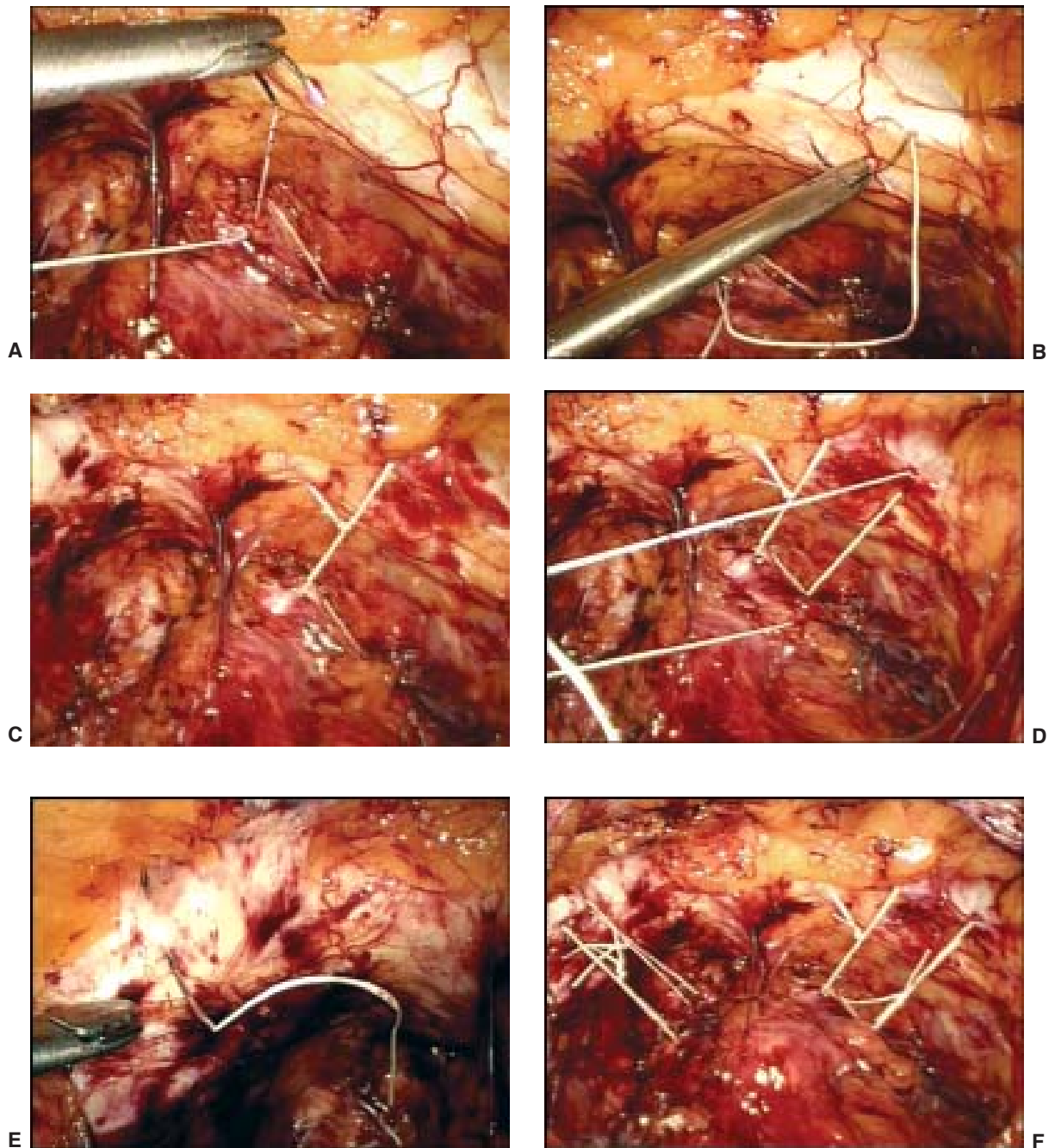
**Figs 12.11A to D:** Paravaginal Repair, left side. The repair on the left begins with placement of the first suture at the apex of the defect around the white line approximately 1-2 cm from the ischial spine (A). We always suture left to right and therefore on the left side, we go through the sidewall first and then through the vagina. Again, when placing the suture around the arcus, the surgeon utilizes both hands laparoscopically; the needle driver with his right hand, and the grasper/retriever with his left hand to initially retract, and then retrieve the needle from the sidewall (B). The needle is reset and then the vagina is again elevated up by the surgeon with his non-dominant hand, the bladder retracted off the pubocervical fascia by the assistant (C) and the suture placed through the vagina, and retrieved with the needle driver in the surgeon's right hand. Maintaining elevation of the vagina with the left hand, the surgeon has easier access to retrieving the needle (D)



**Fig. 12.12:** Hook scissors to cut sutures. All sutures are cut by the surgeon with hook scissors. When tying the knot, the scrub technician places the hook scissors gently in the supra-pubic port, allowing the surgeon to cut the suture as soon as he is done tying the knot down. Hook scissors are much safer and can actually be used to "hook" the suture when its in a difficult position to cut, again maintaining a higher safety level



**Fig. 12.13:** Bilateral paravaginal defect repair



**Figs 12.14A to F:** Burch urethropexy is then completed in patients suffering from stress urinary incontinence. The urethrovesical junction is identified by visualization of the Foley catheter balloon. With elevation of the surgeon's vaginal finger, the vaginal wall lateral to the bladder neck is exposed on each side with the laparoscopic Kitner until glistening white periurethral tissue is exposed. Four Gore-tex sutures (CV-2) are utilized for the procedure. One suture is placed 2 cm lateral to the level of the midurethra and a second at the level of the urethrovesical junction on each side. A double bite is taken through the anterior vaginal wall and each suture is also passed through Cooper's ligament. Extracorporeal knot tying is utilized and a suture bridge is left to avoid excess elevation and tension

surgeon should be prepared to open immediately if hemostasis cannot be obtained. Blind placement of clips or the use of electrocautery is not recommended as this can compromise and/or damage the obturator nerve. Once hemostasis is obtained, the obturator nerve needs to be isolated to ensure that no clips have been placed across it. Another option is the use of Flow Seal, which is thrombin gel type agent that can be placed in the area of bleeding and has been shown to be able to seal off the vessels that are bleeding, even with arterial bleeding. We recommend having this agent available for immediate use in the operating room at all times. If the vessels retract into the obturator canal, obtaining hemostasis can be very difficult and it may be necessary to obtain vascular surgery consult and approach this through the groin.

## CONCLUSION

Although there have been no studies regarding the long-term results of the laparoscopic paravaginal plus colposuspension procedure, one would assume that there is a higher cure rate for the paravaginal plus Burch colposuspension (8 to 12 sutures) compared with the Burch colposuspension only (4 sutures) for the treatment of stress urinary incontinence, because more sutures results in a greater distribution of force to the pelvic floor during episodes of increased abdominal pressure.

## REFERENCES

- Goebell R. Zur operativen Beseitigung der angeharenen Incontinentia Vesicae. *Incontinentia Vesicae Gynakol Urol* 1910;2:187-91.
- Vancaille TG, Schussler W. Laparoscopic bladderneck suspension. *J Laparoendosc Surg* 1991;1:169-73.
- Miklos JR, Kohli N. "Paravaginal Plus" Burch procedure: a laparoscopic approach. *J Pelvic Surg* 1998;4:297-302.
- Kohli N, Miklos JR. Laparoscopic Burch colposuspension: a modern approach. *Contemp Obstet Gynecol* 1997;42:36-55.
- Miklos JR, Kohli N. Laparoscopic paravaginal repair plus Burch colposuspension. *Urology* 2000;56:(suppl 6A)64-69.
- Henley C. The Henley staple-suture technique for laparoscopic Burch colposuspension. *J Am Assoc Gynecol Laparoscopists* 1995;2:441-44.
- Ou CS, Presthus J, Beadle E. Laparoscopic bladder neck suspension using hernia mesh and surgical staples. *J Laparoendosc Surg* 1993;3:563-66.
- Kiilholma P, Haarala M, Polvi H, Makinen J, Chancellor MB. Sutureless colposuspension with fibrin sealant. *Tech Urol* 1995;1:81-83.
- Liu CY. Laparoscopic treatment of genuine urinary stress incontinence. *Clin Obstet Gynecol* 1994;8:789-98.
- Ross JW. Laparoscopic Burch repair compared to laparotomy Burch for cure of urinary stress incontinence. *Int Urogynecol* 1995;6:323-28.
- Ross JW. Two techniques of laparoscopic Burch repair for stress incontinence: A prospective randomized study. *J Am Assoc Gynecol Laparoscopists* 1996;3:351-57.
- Lam AM, Jenkins GJ, Hyslop RS. Laparoscopic Burch colposuspension for stress incontinence: Preliminary results. *Med J Aust* 1995;162:18-22.
- Su TH, Wang KG, Hsu CY, Wei H, Hong BK. Prospective comparison of laparoscopic and traditional colposuspensions in the treatment of genuine stress incontinence. *Acta Obstet Gynecol* 1997;76:576-82.
- Ross JW. Multichannel urodynamic evaluation of laparoscopic Burch colposuspension for genuine stress incontinence. *Obstet Gynecol* 1998;91:55-59.
- Miklos JR, Moore RD, Kohli N. Laparoscopic pelvic floor repair. *Obstet Gynecol* 2002;14:387-95.
- Miklos JR, Moore RD, Kohli N. Laparoscopic management of urinary incontinence, ureteric and bladder injuries. *Curr Opinion Obstet Gynecol* 2001;13:411-17.
- Speights S, Moore RD, Miklos JR. Frequency of lower urinary tract injury at laparoscopic burch and paravaginal repair. Review of 171 cases. *J Am Assoc Gynecol Laparosc* 2000;7:515-18.
- Harris RL, Cundiff GW, Theofrastous JP, et al. The value of intraoperative cystoscopy in urogynecologic and reconstructive pelvic surgery. *Am J Obstet Gynecol* 1997;177:1367-69.
- Stevenson KR, Cholhan HJ, Hartmann DM, et al. Lower urinary tract injury during Burch procedure. *Am J Obstet Gynecol* 1999;181:35-38.
- Paraiso MF, Walters MD, Karram MM, et al. Laparoscopic Burch Colposuspension versus Tension-Free Vaginal Tape: A Randomized Trial. *Obstet Gynecol Surv* 2005;60(3):166-67.