

# Failed Omental Flap Vesicovaginal Fistula Repair Subsequently Repaired Laparoscopically Without an Omental Flap

John R. Miklos, MD and Robert D. Moore, DO

**Background:** Conventional wisdom suggests that vascular interposition flaps are helpful in the treatment of all patients with vesicovaginal fistulas. Complicated fistulas are often treated with interposition omental flaps; however, failed omental flap repairs have not been described without the use of another interposition flap.

**Case:** A 52-year-old woman with a history of cystotomy repair at the time of hysterectomy and a subsequent abdominal omental flap vesicovaginal fistula repair failure underwent a successful repair using a laparoscopic-layered closure of her fistula without omental flap.

**Conclusion:** A failed omental flap vesicovaginal fistula repair can be repaired laparoscopically and without an omental flap.

**Key Words:** vesicovaginal fistula, bladder fistula, vaginal fistula, laparoscopic fistula, omental flap, recurrent fistula, urogenital fistula, laparoscopic vesicovaginal fistula repair

(*Female Pelvic Med Reconstr Surg* 2012;18: 372–373)

Vesicovaginal fistula (VVF) repairs are commonly described using either a laparoscopic, abdominal, or vaginal approach. The literature suggests that an omental interposition flap during a VVF repair will increase the chance of surgical cure.<sup>1</sup> However, there is no level 1 evidence confirming the need for an interposition flap during VVF repair. In fact, scientific articles encourage the use of omental flaps in both benign and malignant conditions,<sup>2,3</sup> but there is paucity in the literature as to the most appropriate technique when a fistula repair using an omental flap fails. We report on a single patient who failed a laparotomy approach to a VVF repair using an omental flap and whose subsequent successful repair was performed using a laparoscopic approach using a layered closure technique without an interposition omental flap.

## CASE STUDY

The patient is a 52-year-old gravida 2 para 2 woman with a complaint of a bladder fistula and continuous urine leakage for 5 months. The patient had a total abdominal hysterectomy performed 8 months earlier for fibroids and heavy bleeding. During the hysterectomy, an accidental cystotomy occurred and treatment was attempted by using delayed absorbable sutures for closure as well as 3 weeks of bladder decompression using a transurethral catheter to gravity.

The patient began leaking immediately afterward; and subsequently, VVF was diagnosed by a voiding cystourethrogram. She was taken back to the operating room 3 months later

and underwent an O'Connor repair<sup>4</sup> with an interposition omental flap. The transurethral stents were removed 5 days later, and the transurethral catheter was removed 6 weeks after the repair. The patient described being "dry" for 7 days and then began leaking urine again. A computed tomographic scan confirmed the VVF, and a transurethral catheter was reinserted for 6 weeks in an attempt at spontaneous closure.

Only 10 days after removal of her catheter, she was seen in our office, and a cystoscopy confirmed bilateral ureteral patency and a VVF. After an informed consent, she agreed to a laparoscopic approach to repair the fistula. She was taken to the operating room; a cystoscopy was performed, and a ureteral stent was placed through the fistula and delivered through the vagina to facilitate identification during the dissection. An open laparoscopy was performed at the inferior edge of the umbilicus where a 10-mm port was placed to accommodate the laparoscope. Three other ports were placed under direct vision. A 5-mm port was placed suprapubically and in the right paramedian, and a 10-mm port was placed in the left paramedian area. Once adhesions were lysed and adequate access to the vesicovaginal area was achieved, an end-to-end anastomosis sizer was placed into the vagina to elevate the apex and to facilitate dissection. The bladder was retrogradely filled with normal saline until the vesicovaginal reflection could be adequately identified. The vesicovaginal space was dissected using endoscopic scissors. Severe adhesions and omentum had to be meticulously dissected in this space. Laparoscopic identification of the ureteral stent confirmed entry into the fistulous tract. The tract was excised from both the vaginal and bladder areas, and dissection was continued approximately 2 cm distal to the most distal aspect of the VVF tract, allowing for a complete separation of the common area of attachment between the bladder and the vagina.

After adequate dissection and mobilization of the vaginal and bladder fistula tracts, a multi-layered closure of the newly excised fistula tract was performed. This is not a modification of the O'Connor technique and has been previously described.<sup>2</sup> A single layer of 2/0 Vicryl suture was placed in an interrupted figure-of-eight fashion to close the vagina. A double-layer closure of 3/0 Vicryl suture was placed in a figure-of-eight fashion to secure the bladder (Fig. 1). After the first layer of bladder closure, the bladder was retrogradely filled with 400+ mL of indigo carmine/sterile water solution and a clean dry 4 × 4-cm sponge was placed into the cul-de-sac and on the bladder suture line. The sponge was removed, and no evidence of indigo carmine was noted on the sponge. After confirming good primary closure of the bladder, a second layer closure was performed using a 3-O Vicryl suture. Again, the bladder suture line integrity test was performed by filling the bladder with indigo carmine/sterile water solution and placing a clean white 4 × 4-cm sponge in the cul-de-sac and on the suture line. Again, no evidence of indigo staining was noted upon removal of the sponge. All suturing was performed laparoscopically, using extracorporeal knot tying. Cystoscopy was performed after each layer of bladder closure, and bilateral ureteral patency was

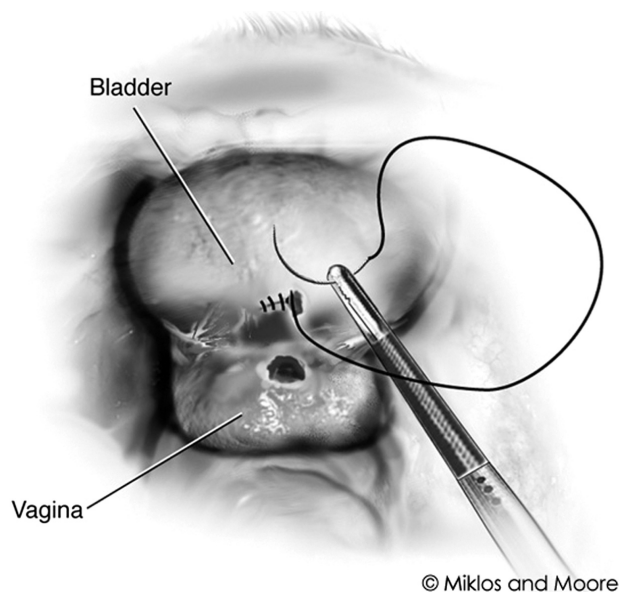
From the Atlanta Urogynecology Associates, Atlanta, GA.

Reprints: John R. Miklos, MD, Atlanta Urogynecology Associates, 3400-C Old Milton Parkway, Suite 330, Alpharetta, GA 30005. E-mail: JohnRMiklos@yahoo.com.

The authors declare that they have nothing to disclose.

Copyright © 2012 by Lippincott Williams & Wilkins

DOI: 10.1097/SPV.0b013e3182751139



Closure of the bladder.

**FIGURE 1.** Three-layered closure techniques: one-layer closure of the vagina and 2-layer closure of the bladder. Here, we see the beginning closure of one of 3 layers.

confirmed. Her suprapubic catheter was removed 14 days after the repair only after confirming success via a voiding cystourethrogram. Two years after her laparoscopic repair, she remains incontinence-free and without a VVF.

## DISCUSSION

There are a number of things that may affect the success of fistula repair, including the following: number of previous attempts; patient's health status; surgeon's experience<sup>5</sup>; and size,<sup>6</sup> fibrosis,<sup>7</sup> and radiation exposure.<sup>8</sup> However, most authors agree that the best chance at closure of the fistula is at the first attempt, and conventional wisdom suggests using a vascularized interposition graft; most commonly, a Martius flap in transvaginal cases and the omentum in abdominal cases can be helpful in ensuring success. Although papers written about using interposition grafts in the treatment of VVF are highly suggestive of greater success, there are no prospective randomized clinical trials proving this theory.

In a study using 24 female mongrel dogs, Sokol et al<sup>9</sup> suggests that a double-layer bladder closure of cystotomy is superior to a single-layer closure and may prevent fistula. The authors adhere to the double-layer bladder closure theory in nonirradiated patients and believe an interposition graft is secondary to meticulous dissection and closure of the fistula tract. The authors do not believe that an abdominal interposition graft is necessary in most cases of VVF if one adheres to meticulous dissection and closure technique. In fact, some surgeons do not

feel the need to close the vagina layer during a VVF repair.<sup>10</sup> The main reason why the authors feel the omental interposition graft is not as viable as the likes of a Martius flap is because there is minimal vascular supply. Flaps work on 2 premises: (1) it functions as a barrier and (2) it introduces vascularity to improve tissue growth and maturation. It has been the authors' experience when reoperating on patients with failed VVFs and omental flaps that there is no increase in vascular supply between the bladder and the vagina, just scar.

Although some might suggest that there is little or no morbidity using an omental graft in experienced hands, the authors believe any added surgical procedure is not without risks. Based on the authors' experience with reentry into abdomens with VVF repairs with omental grafts, the grafts have extensive adhesions, which theoretically increases the chance of extending surgical time, blood loss, and intraoperative morbidity, as well as the potential for pelvic pain associated with adhesive disease. Omental flaps are not a panacea for all non-irradiated VVF repairs; if it were, this patient would not be undergoing a second VVF repair. The authors believe that an omental flap can be used in repair of a VVF at the discretion of the surgeon; however, it is adherence to meticulous dissection and layered closure repair as well as intraoperative testing of each layer of bladder closure, which may be of higher importance to the repair than the placement of any interposition flap.

## REFERENCES

1. Evans DH, Madjar S, Politano VA, et al. Interposition flaps in transabdominal vesicovaginal fistula repairs: are they really necessary? *Urology* 2001;57(4):670–674.
2. Miklos JR, Sobolewski C, Lucente V. Laparoscopic management of recurrent vesicovaginal fistula. *Int Urogynecol J Pelvic Floor Dysfunct* 1999;10:16–17.
3. Kapoor R, Ansar MS, Singh P, et al. Management of vesicovaginal fistula: an experience of 52 cases with a rationalized algorithm for choosing the transvaginal or transabdominal approach. *Indian J Urol* 2007;23(4):372–376.
4. O'Connor VJ, Sokol JK, Bulkley GJ, et al. Suprapubic closure of vesicovaginal fistula. *J Urol* 1973;109:51–54.
5. Kelly J. Vesicovaginal fistulae. *Br J Urol* 1979;51:208–210.
6. Goh JT, Browning A, Berha B, et al. Predicting the risk of failure of closure of obstetric fistula and residual urinary incontinence using a classification system. *Int Urogynecol J Pelvic Floor Dysfunction* 2008;19:1659–1662.
7. Rathee S, Nanda S. Vesicovaginal fistulae: a 12 year study. *J Indian Med Assoc* 1995;93:93–94.
8. Angioli R, Penalver M, Muzii L, et al. Guidelines of how to manage vesicovaginal fistula. *Crit Rev Oncol Hematol* 2003;48:295–304.
9. Sokol AI, Paraiso MF, Cogan SL, et al. Prevention of vesicovaginal fistulas after laparoscopic hysterectomy with electrosurgical cystotomy in female mongrel dogs. *Am J Obstet Gynecol* 2004;190:628–633.
10. von Theobald P, Hamel P, Febraro W. Laparoscopic repair of a vesicovaginal fistula using an omental J flap. *Br J Obstet Gynaecol* 1998;105(11):121.