

## Case Report

# Laparoscopic Davydov Correction of a Failed Gracilis Flap Neovagina in a Patient With Mayer-Rokitansky-Kuster-Hauser Syndrome With a Pelvic Kidney

Christopher R. Moriarty, OMS-III\*, John R. Miklos, MD, and Robert D. Moore, DO\*

From Atlanta Urogynecology Associates, Atlanta Georgia (all authors).

**ABSTRACT** The laparoscopic Davydov procedure is a surgical technique for creation of a neovagina in patients with Mayer-Rokitansky-Kuster-Hauser syndrome (MRKH) or vaginal agenesis. Herein we report its use in creating a neovagina after failure of a previous surgical attempt in a patient with a pelvic kidney, which has not been described to date. The patient, a 28-year-old woman with MRKH in whom creation of a neovagina using bilateral gracilis flaps had been attempted, was unable to have intercourse because of a shortened and scarred vagina. We successfully used the laparoscopic Davydov procedure to create a functional neovagina despite the previous surgery and the presence of a pelvic kidney. The Davydov procedure is an option for use in patients with MRKH with history of unsuccessful neovaginal surgery and can be performed in the presence of a pelvic kidney. *Journal of Minimally Invasive Gynecology* (2013) 20, 262–265 © 2013 AAGL. All rights reserved.

**Keywords:** Laparoscopic; Mayer-Rokitansky-Kuster-Hauser syndrome; MRKH; Neovagina; Pelvic kidney; Vaginal agenesis

**DISCUSS** You can discuss this article with its authors and with other AAGL members at <http://www.AAGL.org/jmig-20-2-12-00455>



Use your Smartphone to scan this QR code and connect to the discussion forum for this article now\*

\* Download a free QR Code scanner by searching for "QR scanner" in your smartphone's app store or app marketplace.

Mayer-Rokitansky-Kuster-Hauser syndrome (MRKH) is the most common cause of vaginal agenesis, with an estimated incidence of 1:1500 to 1:4000 in female infants [1]. Affected individuals have absence of the vagina and uterus (rudimentary uterine tissue may be present), with the normal 46XX female genotype as well as functional ovaries and the development of normal secondary sexual characteristics. Because these individuals are phenotypically normal, diagnosis is often delayed until adolescence, when primary amenorrhea is noted. Associated abnormalities may include skeletal malformations (most often affecting the vertebral column), auditory deficits, and urinary tract anomalies such as duplication of ureters and horseshoe or pelvic kidney [2].

The authors have no commercial, proprietary, or financial interest in the products or companies described in this article.

Corresponding author: Robert D. Moore, DO, Atlanta Urogynecology Associates, 3400-C Old Milton Pkwy, Ste 330, Alpharetta, GA 30005. E-mail: moorer33@hotmail.com

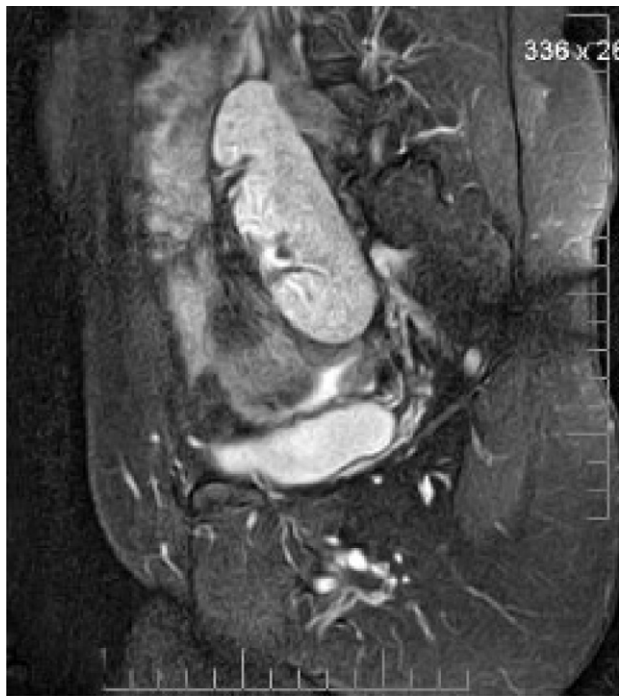Submitted October 29, 2012. Accepted for publication November 19, 2012. Available at [www.sciencedirect.com](http://www.sciencedirect.com) and [www.jmig.org](http://www.jmig.org)

Management of MRKH is challenging because confirmation of the diagnosis has a substantial effect on the patient's sense of femininity. Along with psychologic support, creation of a neovagina is mandatory so that the patient can have a normal sex life [2]. Typically, most young women attempt to create a vaginal canal with the use of dilators. However, this is not always successful, and therefore a surgical approach is often considered.

There are multiple options for creation of a neovagina. The laparoscopic modification of the Davydov procedure is a minimally invasive alternative in which the patient's pelvic peritoneum is used for creation of a neovagina [3]. This procedure has not been as extensively described as some of the more commonly performed neovagina procedures such as the McIndoe or Vecchiotti operations [5]. In addition, in the currently available literature, the presence of a pelvic kidney has been an exclusion criterion for performance of the Davydov procedure because of the potential risk of damage during laparoscopic mobilization of the peritoneum [1,4]. Herein is reported the case of a patient with MRKH with a pelvic kidney in whom previous neovagina construction failed. To create a neovagina in this patient,

**Fig. 1**

Sagittal magnetic resonance image of the pelvic kidney.



we elected to use a laparoscopic modification of the Davydov procedure.

### Case Report

A 42-year-old premenopausal woman came to our office with a history of congenitally shortened or absent vagina and uterine agenesis as a result of MRKH. She had undergone previous surgery to create a neovagina using gracilis flaps. However, the length achieved was insufficient to allow intercourse between the patient and her husband. On initial examination, the vaginal length was 2.5 to 3 cm, with scarring at the apex and some lateral bulging at each side of the introitus. In addition, the patient had a history of cleft palate

repair, difficult intubation, and a right-sided pelvic kidney (Fig. 1). The patient elected to proceed with the Davydov laparoscopic technique to elongate the neovagina after she was made aware of the possibility of encountering substantial adhesive disease and possible injury to the pelvic kidney during the laparoscopic portion of the procedure. In addition, the patient understood that, depending on the laparoscopic findings, the procedure might not be able to be completed if the pelvic kidney was in a position that would prevent mobilization of the peritoneum to create the neovagina.

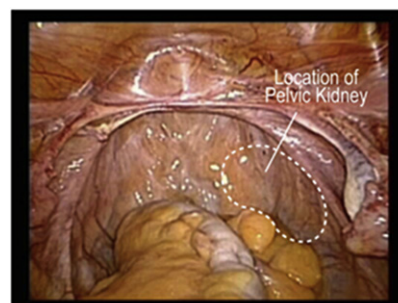
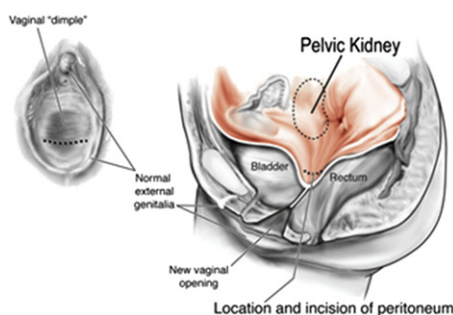
With the patient under general anesthesia, cystoscopy was performed, and a right ureteral stent was placed and maintained during surgery to aid in visualization of the ureter and pelvic kidney. In addition, a Foley catheter was placed, and the vagina was inspected before proceeding with the laparoscopic portion of the procedure. Two 10-mm ports were placed, one at the inferior edge of the umbilicus to accommodate the laparoscope and the other in the left paramedian area. Five-millimeter ports were also placed in the right paramedian area and in the suprapubic region.

Severe bowel adhesive disease was encountered. However, it was reduced without complication to the point at which we were able to identify the anatomic landmarks in the lower abdomen and pelvis and completely free the pelvis of all adhesions. Minimal trauma or bleeding was encountered within the pelvic peritoneum. The right pelvic kidney was identified and thought not to be in a position to preclude completion of the procedure (Fig. 2). Both ureters were identified.

A vaginal approach was then used to make a horizontal incision at the apex of the shortened vagina. Using gentle blunt dissection, the potential space between the bladder and rectum was created. An EEA sizer was passed into the newly created space until it could be directly visualized through the peritoneum from above via laparoscopy. A horizontal incision was then made through the peritoneum, abutting the head of the end-to-end anastomosis (EEA) sizer, creating a communication between the peritoneal cavity and the vaginal opening. This opening was then widened to accommodate at least 2 fingers. A large EEA sizer

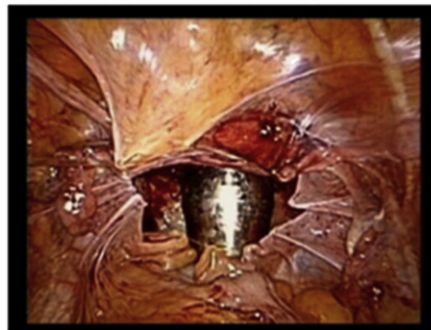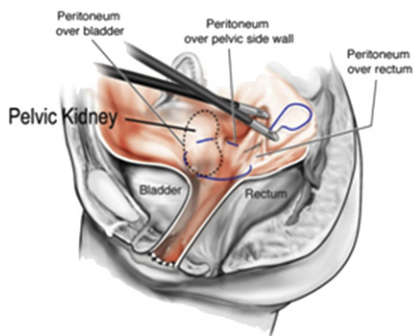
**Fig. 2**

Location of the pelvic kidney in the pelvis.



**Fig. 3**

Purse string closure of peritoneum to create an apex of the neovagina. Note the relationship of the pelvic kidney to the peritoneal suture.



(No. 32) was then able to be passed through the opening of the vaginal apex and the peritoneum. The peritoneum was then brought down to the vaginal epithelium using interrupted sutures of polyglactin 910 (2/0) circumferentially.

A purse string suture of 0 polydioxanone was placed circumferentially in the peritoneum around the pelvic brim, enabling closure and formation of the new vaginal apex (Figs. 3 and 4). When creating the vaginal apex using the Davydov procedure with the peritoneal purse string suture, specific care is taken to avoid the ureters and rectum. In this patient with a pelvic kidney, we were careful to grasp only the peritoneum over the kidney and not enter the body of the kidney itself. A second suture of polyglactin 910 (2/0) was used for extra support. Before removing all port sites, the patient was given 1 ampule of indigo carmine, and cystoscopy was performed to ensure bilateral ureteral patency. The vaginal length created was 11 cm. Vaginal packing was placed, which was removed 48 hours after surgery. On removal of the packing, the patient was able to pass dilators immediately to maintain patency.

The patient returned 4 weeks after hospital discharge for follow-up. Vaginal length was measured at 10 cm, with

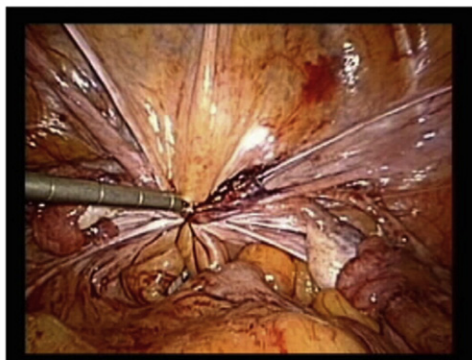
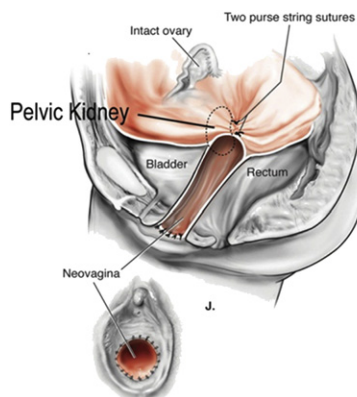
adequate width at the apex. She was using dilators and vaginal estrogen cream daily without problem. In addition, the vagina appeared well rugated, with appropriate estrogenization, and was absent of any discharge. Continued dilator passage was recommended until 6 to 8 weeks postoperatively, at which time the patient could attempt to be sexually active. At 6-month follow-up, the patient reported successful pain-free intercourse and was satisfied with the outcome. Vaginal estrogen was recommended to be used 3 to 4 times weekly for 1 year postoperatively. Renal function has been normal at follow-up with her internist.

### Discussion

The laparoscopic modification of the Davydov procedure is a relatively new technique for creation of a neovagina in patients with vaginal agenesis. It uses the patient's own pelvic peritoneum to create the vaginal canal and the apex of the vagina. Secondary to this, there are no raw surface areas and no grafts that must heal into place; therefore, patients can begin sexual relations relatively quickly, and very little dilation is necessary. Patients use dilators only

**Fig. 4**

Closure of the purse string suture and new apex of the vagina.



to maintain length and patency until the vaginal-peritoneal junction is healed. At this point, they can begin intercourse and sexual relations. The procedure is both minimally invasive and highly effective in terms of post-surgical FSFI (Female Sexual Function Index) scores [6,7] and postoperative measurements [6]. In addition, studies have demonstrated the presence of stratified squamous epithelium, similar to that found at the vaginal introitus, covering the entire surface of the peritoneal tissue used for the neovagina by as few as 90 days after surgery [8]. This finding may help to explain the high FSFI scores in patients undergoing the Davydov procedure.

The laparoscopic Davydov procedure has not yet been described in patients with unsuccessful previous surgical attempts at creation of a neovagina. The present case shows that this is possible, inasmuch as there was a successful outcome and creation of a 10-cm functional vaginal canal with adequate width. The benefits of the procedure in this type of case are that the scar tissue at the apex can be divided and the peritoneum can be used to add length to the new vaginal canal. Increased risks such as bladder and bowel injuries are possible in patients with previous surgery, and care must be taken in the dissection of the space between these 2 organs. However, in the present case, no complications were encountered.

We were able to perform the procedure despite the presence of a pelvic kidney, which also has not been reported to date. In 2 previous studies describing the Davydov procedure, patients with a pelvic kidney were either excluded from participation [1] or assigned to another group

undergoing a different neovaginal procedure [4]. In the present case, we demonstrated that although great care must be taken to avert unintentional injury to the pelvic kidney, the laparoscopic and vaginal portions of the Davydov procedure can be safely accomplished. However, depending on the size and position of the pelvic kidney, this may not be possible in all patients, and care must be individualized.

## References

1. Fedele L, Frontino G, Restelli E, Ciappina N, Motta F, Bianchi S. Creation of a neovagina by Davydov's laparoscopic technique in patients with Rokitansky syndrome. *Am J Obstet Gynecol*. 2010;202:33.e1–33.e6.
2. Creatas G, Deligeoroglou E. Vaginal aplasia and reconstruction. *Best Pract Res Clin Obstet Gynaecol*. 2010;24:185–191.
3. Ismail I, Cutner A, Creighton S. Laparoscopic vaginoplasty: alternative techniques in vaginal reconstruction. *BJOG*. 2006;113:340–343.
4. Bianchi S, Frontino G, Ciappina N, Restelli E, Fedele L. Creation of a neovagina in Rokitansky syndrome: comparison between two laparoscopic techniques. *Fertil Steril*. 2011;95:1098–1100.e1–3.
5. Bradshaw KD. Anatomic disorders. In: Schorge JO, Schaffer JJ, Halvorson LM, Hoffman BL, Bradshaw KD, Cunningham FG, editors. *Williams Gynecology*. New York, NY: McGraw-Hill; 2008. p. 402–425.
6. Liu X, Liu M, Hua K, Li B, Guo SW. Sexuality after laparoscopic peritoneal vaginoplasty in women with Mayer-Rokitansky-Kuster-Hauser syndrome. *J Minim Invasive Gynecol*. 2009;16:720–729.
7. Zhou JH, Sun J, Yang CB, Xie ZW, Shao WQ, Jin HM. Long-term outcomes of transvestibular vaginoplasty with pelvic peritoneum in 182 patients with Rokitansky's syndrome. *Fertil Steril*. 2010;94:2281–2285.
8. Marques H, dos Santos F, Lopes-Costa PV, dos Santos A, da Silva B. Creation of a neovagina in patients with Rokitansky syndrome using peritoneum from the pouch of Douglas: an analysis of 48 cases. *Fertil Steril*. 2008;90:827–832.