

Laparoscopic Sacral Colpopexy

ROBERT D. MOORE, D.O.

CO-DIRECTOR OF UROGYNECOLOGY & RECONSTRUCTIVE PELVIC SURGERY
ATLANTA CENTER FOR LAPAROSCOPIC UROGYNECOLOGY
ATLANTA UROGYNECOLOGY ASSOCIATES
ATLANTA, GA

JOHN R. MIKLOS, M.D.

CO-DIRECTOR OF UROGYNECOLOGY & RECONSTRUCTIVE PELVIC SURGERY
ATLANTA CENTER FOR LAPAROSCOPIC UROGYNECOLOGY
ATLANTA UROGYNECOLOGY ASSOCIATES
ATLANTA, GA

ABSTRACT

Sacral colpopexy is the gold standard for vaginal vault suspension throughout the literature. The operation is considered to be invasive yet very effective. The laparoscopic approach to the sacral colpopexy is not only effective but can have minimal morbidity in the correct surgeon's hands. The authors have performed more than 500 sacral colpopexy via laparoscopy with minimal morbidity and thus share their technique with the reader.

INTRODUCTION

Abdominal sacral colpopexy remains one of the most successful operations for the treatment of vaginal vault prolapse (Fig. 1) with excellent results on long-term follow-up.¹⁻³ The laparoscopic approach is used in an attempt to minimize the size of the abdominal incision and thus the patient's morbidity.⁴⁻⁶ If the surgeon uses laparoscopy as a means of surgical access and performs the sacral colpopexy in the same manner as in the open abdominal approach, the operative cure rate should theoretically be equivalent.

SURGICAL TECHNIQUE

The patient is taken to the operating room and is placed in the dorsal lithotomy position with adjustable Allen stirrups. A three-way 16-Fr Foley catheter is placed for gravity drainage. Inflatable sequential compression devices are placed on the patient's lower extremities for deep vein thrombosis (DVT) prophylaxis. A 48-hour bowel preparation is used for all of our laparoscopic patients. This preparation helps decompress the bowel for better visualization and helps minimize the risk of infection

if bowel injury occurs. Two days prior to surgery, the patient is placed on a full liquid diet (shakes, pudding, and so on), and the day prior to surgery only clear liquids are allowed. The afternoon prior to surgery, the patient drinks 8 oz of magnesium citrate to clean out the bowels. We also do not recommend the use of nitrous oxide for an anesthetic agent during laparoscopy because this can cause bowel distention during the procedure and increase the risk of bowel injury.

Port placement is based on the surgeon's preference, skill, and acquired technique. We use a 10-mm suturing port in the left paramedian region, and two 5-mm ports, one in the suprapubic region and the other in the right paramedian region (Fig. 2). The surgeon stands on the patient's left side and completes all needle passing, suturing, needle retrieving, and knot tying by themselves using the left paramedian and suprapubic port. The assistant stands on the patient's right side and drives the camera, using the right lower port for retraction, suction/irrigation, and so on. Once the operative ports have been placed, the vagina is elevated with an EEA™ sizer (Ethicon, New Brunswick, NJ) and the peritoneum overlying the vaginal apex is dissected anteriorly, exposing the apex of the pubocervical fascia (Fig. 3a). If the edge of the bladder is difficult to identify secondary to scar tissue, the bladder can be retrograde filled through the three-way Foley catheter with sterile water and then carefully dissected off the anterior segment. We take this dissection approximately one third to one half the way down the anterior wall.

Next, we dissect out the space between the rectovaginal fascia and the rectum. This dissection opens the rectovaginal space, and the dissection is taken down to within 3 cm of the perineal body (Fig. 3b). If bleeding is encountered, it can be stopped with bipolar electrocautery or surgical clips. A separation between the rectovaginal and pubocervical fascia confirms an enterocele at the apex (Fig. 4).⁷ If a small enterocele is present, it should be repaired in a site-specific fashion by imbricating the stretched vaginal epithelium between the apical edges of the pubocervical and rectovaginal fascia.⁸ A permanent suture can be used in a continuous purse-string fashion or in an interrupted fashion. A large enterocele

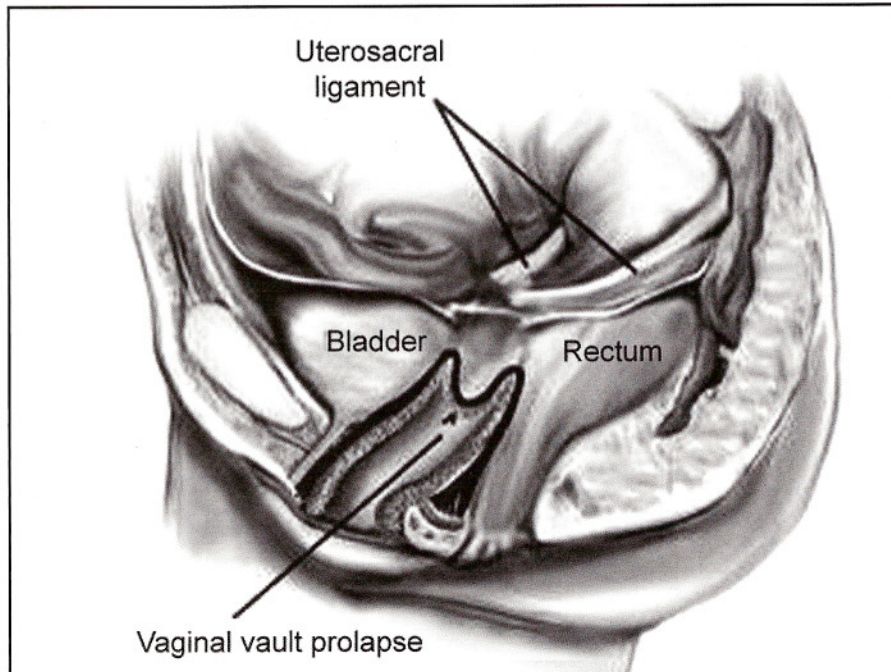


Figure 1. Vaginal vault prolapse.

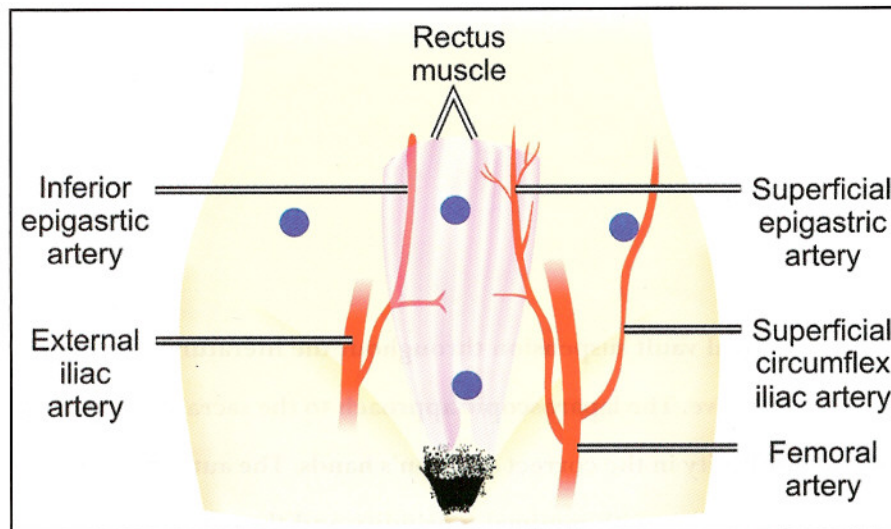


Figure 2. Laparoscopic port placement.

(Figs. 5a & 5b) should be resected (Fig. 5c) and the cuff re-approximated with absorbable sutures so the excessive vaginal epithelium is not used as a point of mesh attachment. Theoretically, suturing the mesh to the enterocele sac instead of the more supportive pubocervical and rectovaginal fascia may predispose the patient to an increased risk of mesh erosion, suture pullout, or surgical failure.

Attention is then directed to the sacral promontory and the presacral space. The peritoneum overlying the sacral promontory is incised longitudinally and this peritoneal incision is extended to the cul-de-sac (Figs. 6a & 6b). A laparoscopic dissector is used to expose the anterior ligament of the sacral promontory through blunt dissection (Fig 6c). The peritoneum on the sidewall is incised and freed up beneath the ureter so that the mesh can be retroperitonealized at the end of the operation. Hemostasis is achieved using either coagulation or surgical clips.

A 12 cm × 4 cm polypropylene mesh graft is fashioned into a "Y" shape so there is an anterior and posterior leaf of the mesh. Typically, the anterior leaf is approximately 3 cm to 4 cm long and the posterior leaf is longer at 5 cm to 6 cm so that it can be brought down deeper into the rectovaginal space. The mesh is then introduced into the abdominal cavity through a 10-cm or 12-cm port. The posterior leaf is sutured back to the tail of the mesh to keep it out of the way, and the anterior leaf is sutured in place first. The vaginal apex is then directed anterior and cephalad, exposing the pubocervical fascia for application of the surgical graft. The anterior leaf of the mesh is then sutured to the pubocervical fascia with three pairs of 2-0 nonabsorbable sutures beginning distally and working toward the rectovaginal fascia apex (Fig. 7). We use nonabsorbable sutures and tie extracorporally with a closed-loop knot pusher, which is time-saving and efficient.

The first suture is placed through the mesh and then through the pubocervical fascia, being careful to avoid the bladder edge. Once the anterior leaf is sutured in place, the posterior leaf is then released and sutured in place in a similar fashion. The most distal suture is typically placed through the vagina first (being careful to avoid the rectum), then brought through the mesh, and

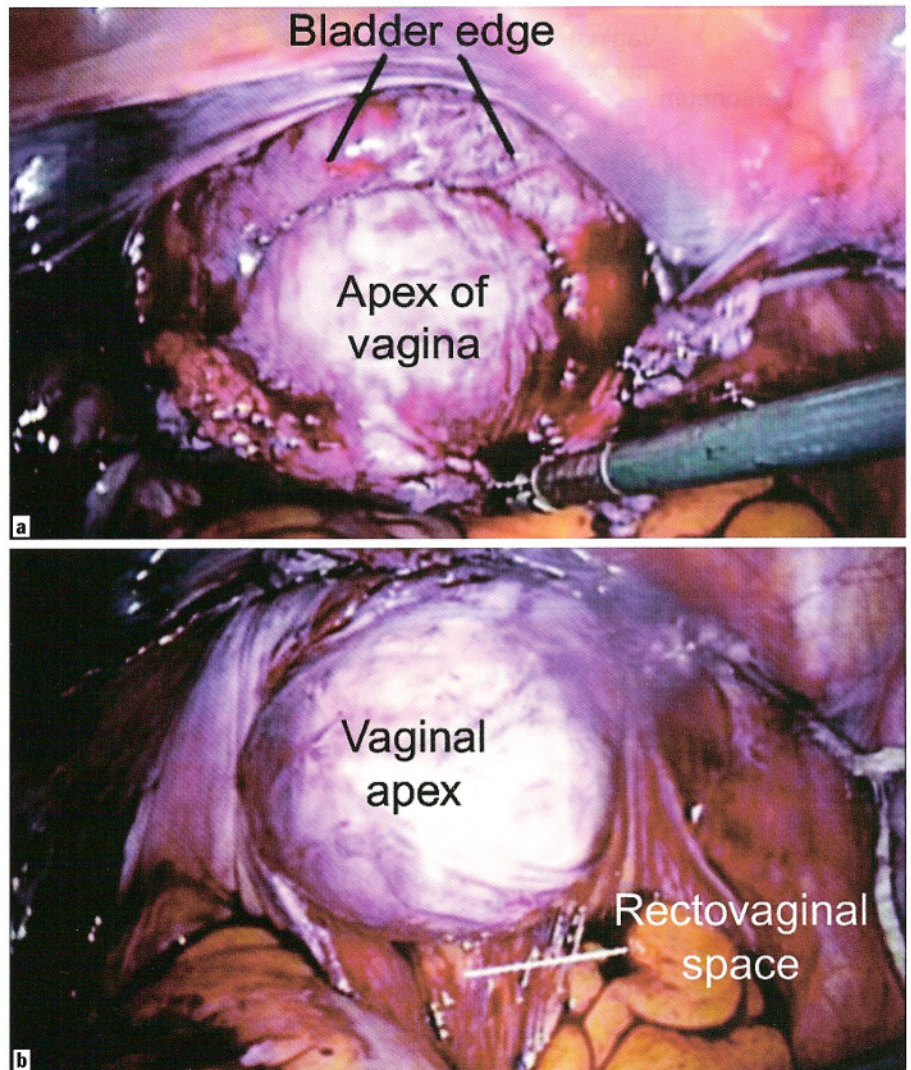


Figure 3. (a) Exposing the pubocervical fascia at the vaginal apex. (b) Exposing the rectovaginal septum at the vaginal apex.

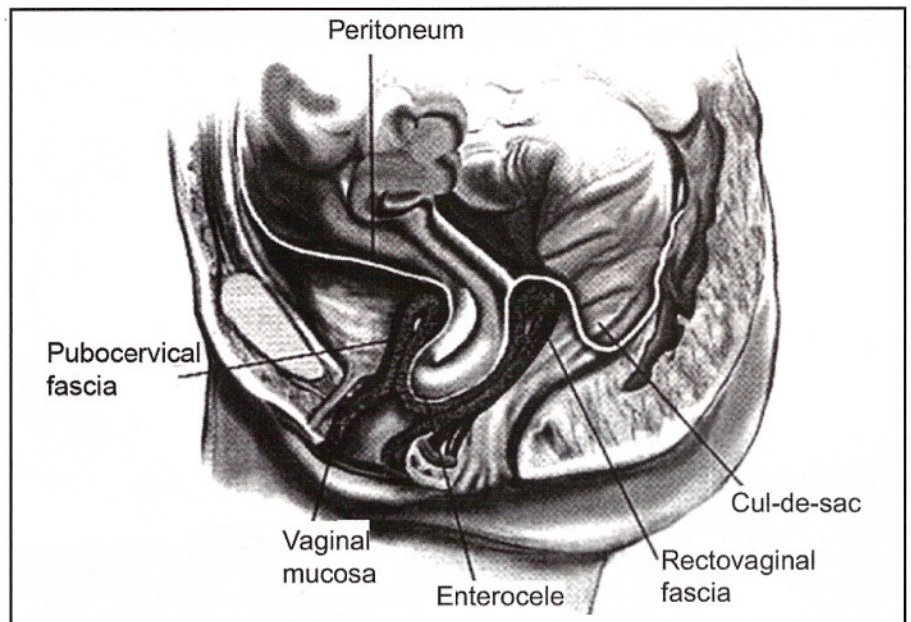


Figure 4. Enterocele - peritoneum in direct contact of vaginal epithelium with no intervening fascia.

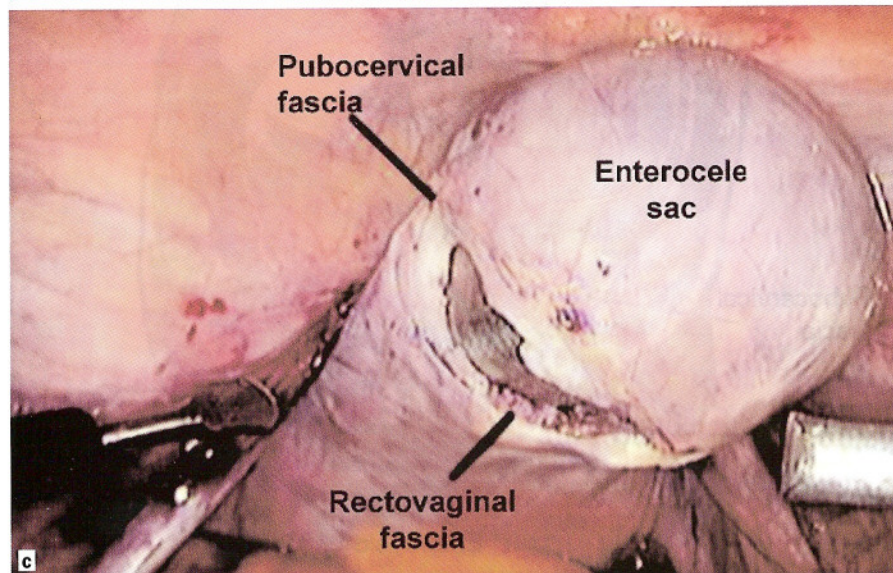
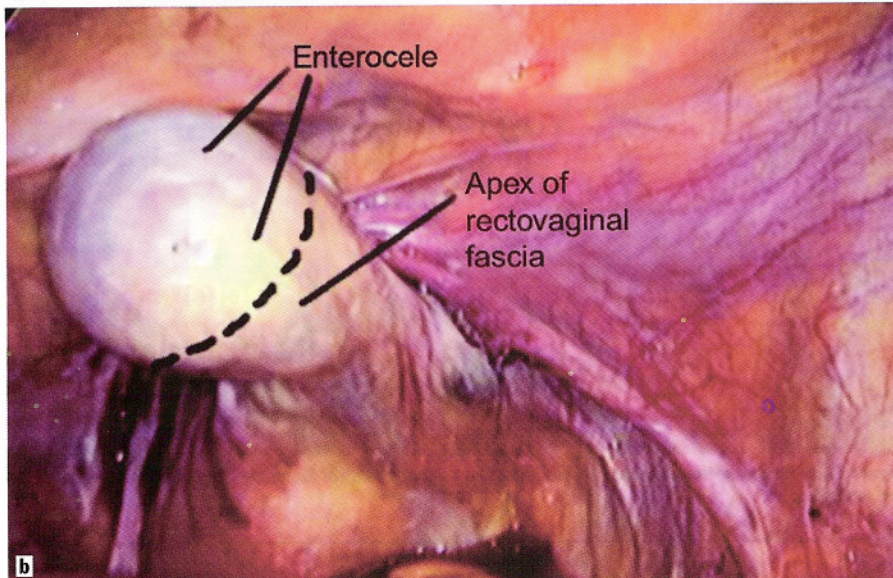
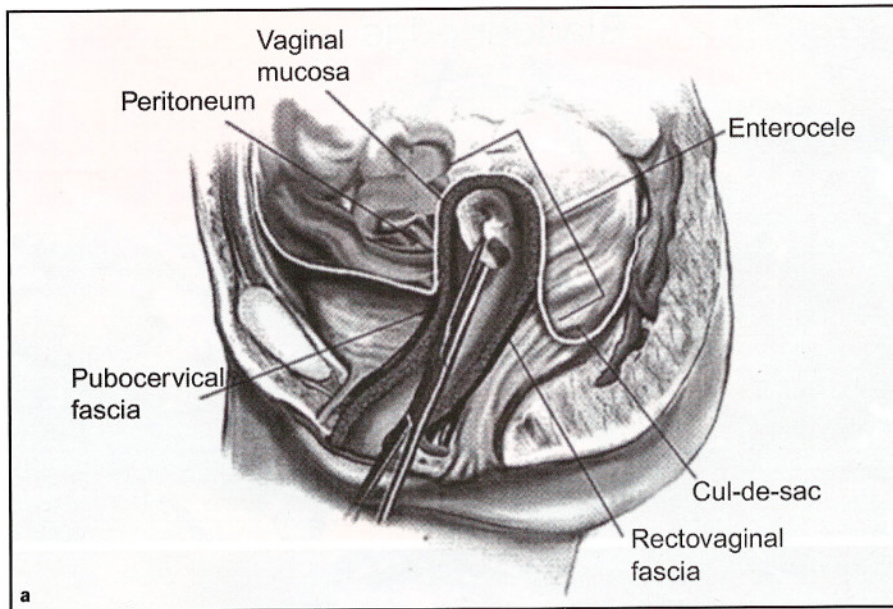


Figure 5. (a). Large enterocele. (b) Large enterocele. (c) Dissecting and removing the large enterocele sac.

then tied down into position. The remaining sutures are taken through the mesh and the vagina, typically all at once, and a total of six to eight sutures are used to suture the posterior leaf into place (Fig. 8). The surgeon should attempt to take stitches through the entire thickness of the vaginal wall, excluding the vaginal epithelium.

If a hysterectomy is completed at the time of the surgery, the cuff is reapproximated in the normal fashion prior to mesh placement and the procedure is then completed in the identical fashion as described previously. Some have suggested the use of a double-layer closure of the vaginal cuff to help decrease the rate of mesh erosion, but we do not routinely do this and have seen no increased rate of cuff erosion.⁹ However, we do feel it is very important to keep the sutures that are being placed to hold the mesh in place away from the vaginal cuff, as suturing the mesh right into the cuff can lead to an extrusion in the suture line.

The vagina is then elevated into its normal natural position in the pelvis, and the surgeon sutures the free end of the Y-shaped mesh to the anterior longitudinal ligament of the sacrum using two No. 0 nonabsorbable sutures (Fig. 9). The mesh should be attached with minimal tension on the vagina (Figs. 10a & 10b). After reducing intra-abdominal pressure and inspecting the presacral space for hemostasis, the peritoneum is reapproximated with 2-0 polyglactin sutures (Fig. 11). The most important aspect of retroperitonealizing the mesh is not necessarily to cover over all the mesh but is to eliminate the open space between the mesh and the right pelvic side wall where the bowel could potentially become entrapped and obstructed or ischemic. Once the repair is completed, cystoscopy is completed to ensure ureteral patency and to ensure that there is no suture penetration into the bladder or damage to the bladder from dissection or suture placement.

POTENTIAL COMPLICATIONS AND INJURIES

Lower Urinary Tract Injuries

Potential injuries can occur to the ureters or to the bladder during the repair. The ureters should be identified at the beginning of the operation. Clearly, the right ureter is at more risk

of injury, secondary to the placement of the mesh on the sacrum on the right side of the colon. The right ureter is identified at the pelvic brim prior to dissection down into the presacral space. As this space is opened and the incision is extended down into the pelvis on the right side wall, the ureter should be clearly visualized throughout the dissection and is actually released away from the operative field with the dissection. The ureters could also potentially be compromised during suture placement of the mesh arms onto the anterior and posterior vagina, specifically the most distal lateral sutures on the anterior wall near the edge of the bladder where the ureters are entering into the bladder (a good dissection will help avoid this danger area) and the lateral sutures of the posterior leaf near the uterosacral ligaments.

Cystoscopy is performed at the end of the procedure to ensure ureteral patency. If ureteral obstruction is identified, the suture causing this must be identified and removed and ureteral patency confirmed. If any evidence of compromise or injury is identified to the ureter, a ureteral stent should be placed and left in place for 14 days to 21 days. If a suture is seen penetrating the bladder, it must be removed (laparoscopically) and replaced away from the bladder and no further treatment is necessary. If cystotomy occurs during the original dissection of the bladder off of the vagina, this should be repaired laparoscopically with a double-layer closure with delayed absorbable sutures. The procedure can still be completed and mesh placed, but care should be taken to try to keep the mesh away from the suture line in the bladder. The bladder should be drained for an extended period of time with this type of an injury (7 days to 10 days) to ensure proper drainage and healing. Overall, the risk of lower urinary tract injury is lower with sacral colpopexy than with other vault suspensions, such as uterosacral ligament suspension.

Bowel Injury

The bowel can be injured with the lysis of adhesions or with the dissection of the rectum off of the posterior wall of the vagina. A proper 48-hour bowel preparation described previously is vital to help decrease the risk of bowel injury, as this actually deflates the small

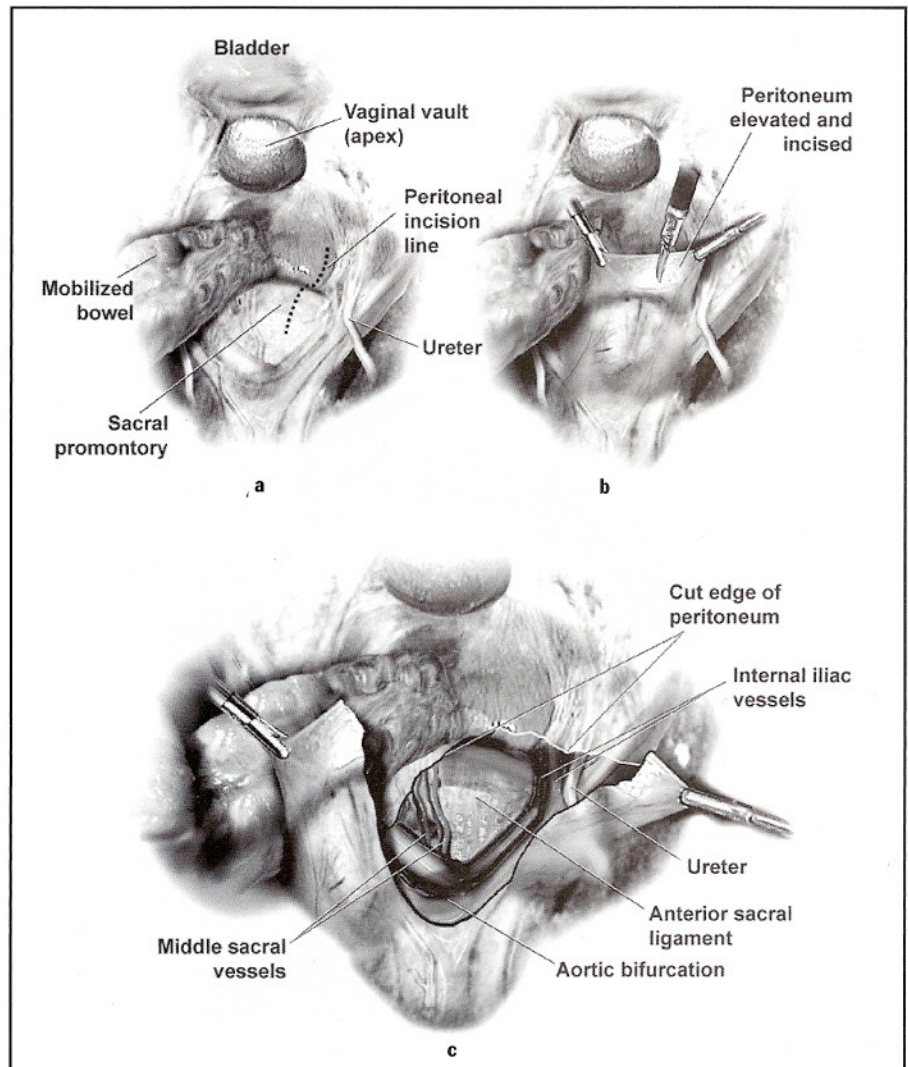


Figure 6. (a) Incisions of peritoneum over sacral promontory. (b) Incisions of peritoneum over sacral promontory. (c) Exposing the anterior ligament of the sacrum.

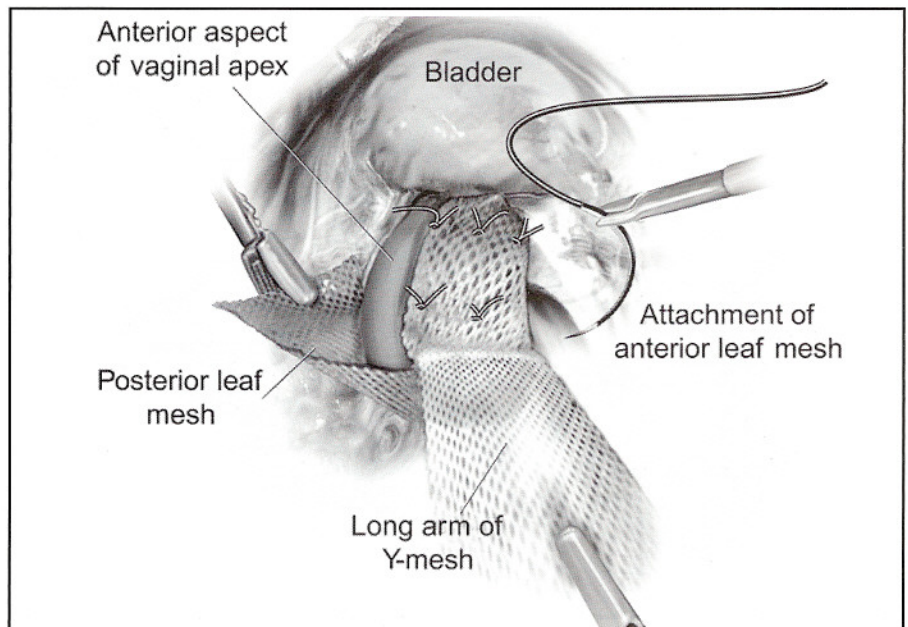


Figure 7. Suturing the mesh to the anterior vaginal pubocervical fascia.

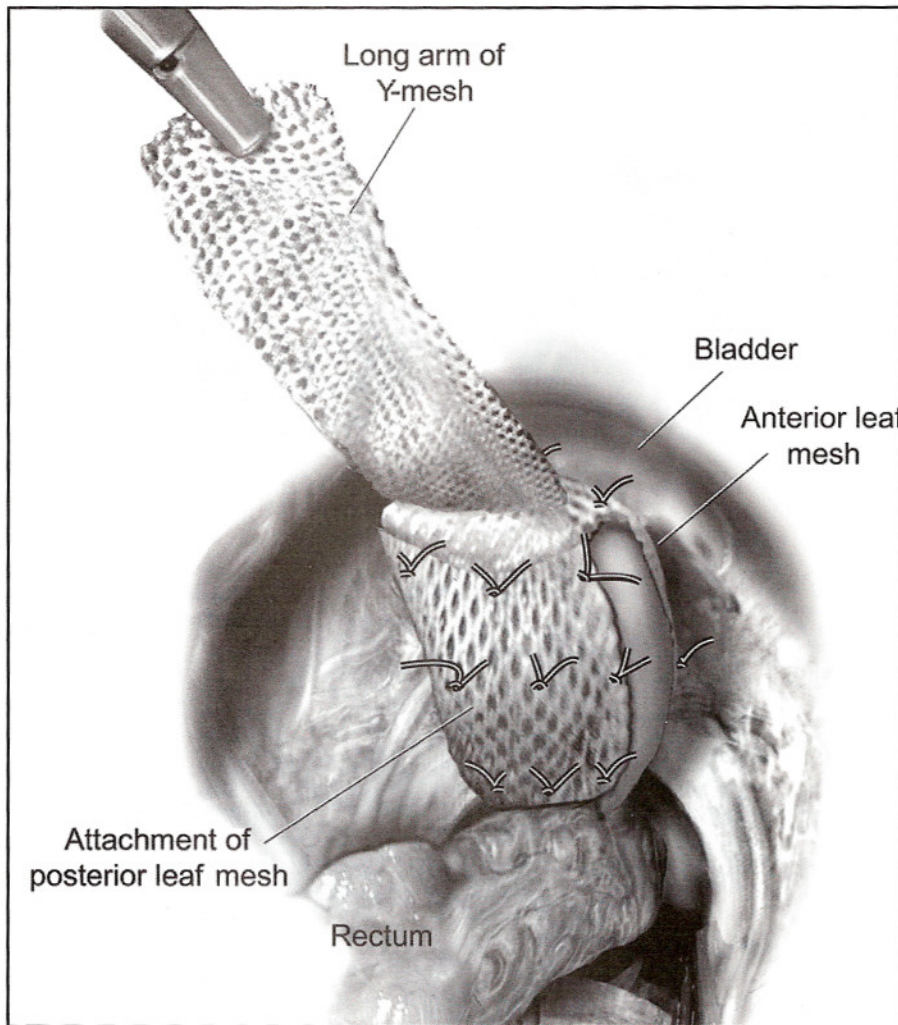


Figure 8. Suturing the mesh to the posterior vaginal rectovaginal fascia.

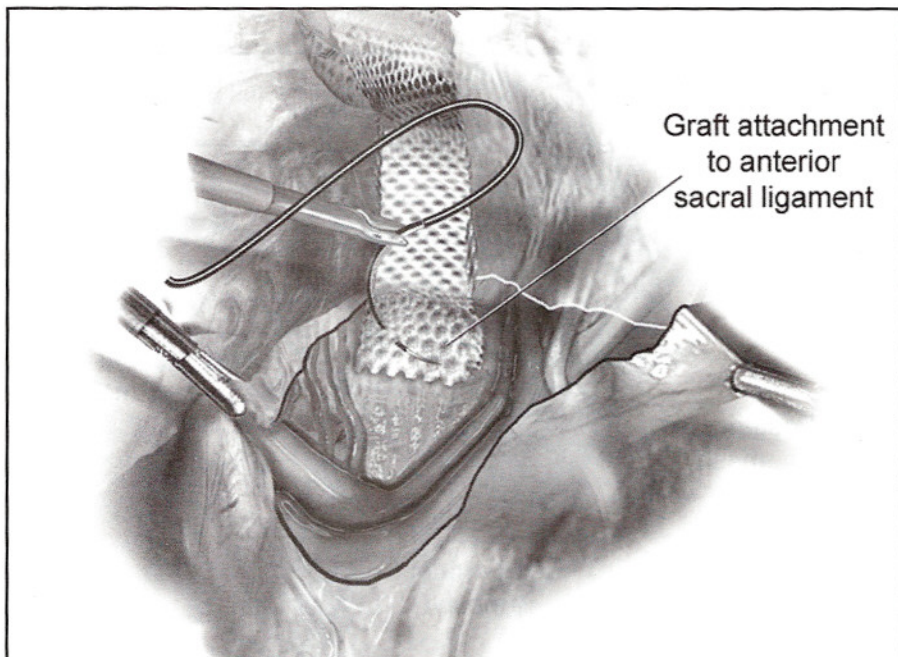


Figure 9. Suturing the mesh to the anterior ligament of the sacrum.

and large bowel and makes it much easier to get the bowel out of the pelvis and have it stay in the upper abdomen and out of the surgical field. Additionally, the use of nitrous oxide should be avoided as well as an anesthetic agent, as this will cause the bowel to become distended and inflated, increasing the risk of injury. If a small bowel injury occurs, primary repair laparoscopically is recommended and if a proper bowel preparation was completed, the mesh sacral colpopexy can be completed. However, antibiotic coverage should be completed for 1 week postoperatively. If the rectum or large bowel is injured during the dissection into the rectovaginal space, primary repair can be completed if proper bowel preparation was completed. However, the mesh is not recommended to be placed following a large bowel injury. Certainly, antibiotic coverage is warranted postoperatively as well.

Vascular Injuries

As with any advanced pelvic surgical procedure, a thorough knowledge of the pelvic anatomy and vasculature is required prior to attempting laparoscopic sacral colpopexy. The overall risk for bleeding is actually quite low; however, if it does occur it can be a life-threatening event. Our average blood loss in over 500 cases over the past 4 years has been less than 75 cc, and we have not had to give any blood transfusions for intra-operative bleeding and only one blood transfusion postoperatively. The average blood loss for laparoscopic reconstruction is actually much less than with laparotomy secondary to more precise dissection and better visualization with laparoscopy, with the benefit of also eliminating the bleeding encountered with a large abdominal wall incision. There is actually minimal risk of bleeding or major vasculature injury with the dissection of the vaginal cuff. This area can be quite vascular, especially down in the rectovaginal space, but it is typically venous in nature and can be easily controlled with cauterization or surgical clips.

One should always identify and know the location of the ureters prior to any cauterization or clipping. However, dissection into the presacral space has the potential for catastrophic bleeding. The patient is placed in deep Trendelenburg positioning with a left tilt so the bowel may be placed in the upper

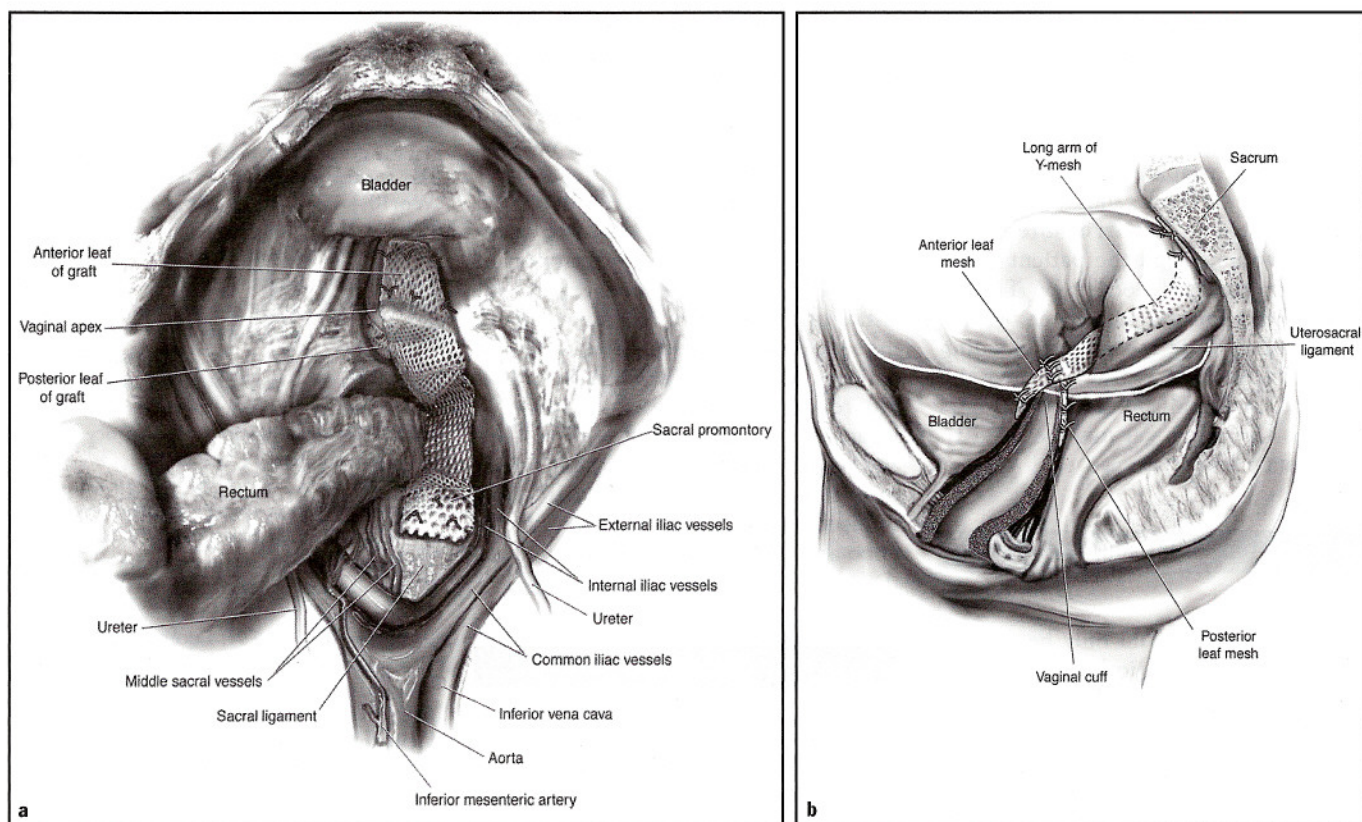


Figure 10. (a) Minimal tension is used when attaching the mesh to the sacrum. (b) Minimal tension is used when attaching the mesh to the sacrum.

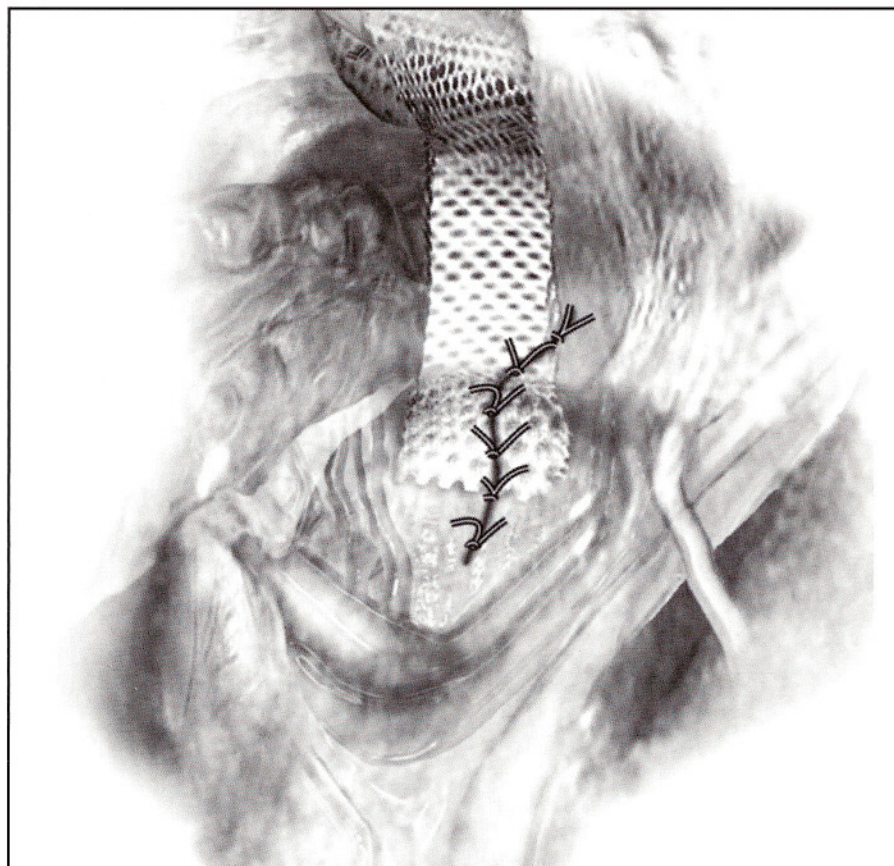


Figure 11. Reapproximating the peritoneum over the sacral colpopexy mesh.

abdomen and the rectum will fall off to the patient's left side. The right common iliac artery and vein are identified, as is the ureter. The peritoneum is tented using fine graspers and the peritoneum incised over the sacral promontory. The presacral space is carefully dissected until the presacral ligament is reached, and this area is carefully cleaned with a laparoscopic Kittner dissector until the white of the ligament is seen. The middle sacral artery is identified and the surgeon is ensured of finding a vessel-free area to suture or attach the mesh. One must be careful, as on occasion the left common iliac vein can traverse this area as well.

If bleeding is encountered during the dissection or down in the sacral hollow, it can be life-threatening and rapid conversion to laparotomy should be considered and prepared. Bipolar electrocautery, surgical clips, or hemostatic sutures may be used laparoscopically to try to control the bleeding, but again the position of the ureter must be identified to ensure it is away from the surgical field. Thrombin gel agent may be used laparoscopically and can be helpful in controlling both arterial and venous bleeding. We have utilized this

material in several incidences and have had excellent clinical results, and to date have not had to convert any patient to laparotomy.

If bleeding cannot be controlled, a conversion to laparotomy is required and packing/pressure should be placed immediately to control bleeding, restore volume, and the patient given blood products if necessary. Thumb tacks with bone wax have been used in the sacral hollow to control bleeding vessels that have retracted into the sacrum, and again hemostatic agents such as thrombin gel may be used to help obtain hemostasis as well.

CONCLUSION

Laparoscopy should only be considered a mode of surgical access, which should not significantly change the technique of operative reconstructive surgery. Laparoscopy benefits the surgeon by improving visualization, decreasing blood loss, and magnifying

the pelvic floor defects that must be repaired. Other advantages — including less postoperative pain, shorter hospital stays, shorter recovery time, and earlier return to a better quality of life — have also been described in the literature to date. Disadvantages often cited in the literature include increased operative time and associated increased costs. The authors' personal experience is the operative time is similar and in many cases reduced, especially for patients with a high body mass index. However, complex operative laparoscopy is associated with a steep and lengthy learning curve, after which operative time can be significantly reduced based on the surgeon's experience and laparoscopy skills as well as the quality of the operative team. **STI**

REFERENCES

1. Maher C, Baessler K, Glazener C, et al. Surgical management of pelvic organ prolapse in women. *Cochrane Database Syst Rev* 2007 July 18;(3):CD004014.
2. Higgs P, Goh J, Krause H, et al. Abdominal sacral colpopexy an independent prospective long-term follow-up study. *Aus NZ J Obstet Gynaecol* 2005 Oct;45(5):430-4.
3. Limb J, Wood K, Weinberger M, et al. Sacral colpopexy using mersilene mesh in the treatment of vaginal vault prolapse. *World J Urol* 2005 Feb;23(1):55-60. Epub, 11 Nov 2004.
4. Rozet F, Mandron E, Arroyo C, et al. Laparoscopic sacral colpopexy approach for genito-urinary prolapse: experience with 363 cases. *Eur Urol* 2005 Feb;47(2):230-6.
5. Cosson M, Rajabally R, Bogaert E, et al. Laparoscopic sacrocolpopexy, hysterectomy and burch colposuspension: feasibility and short-term complications of 77 procedures. *J Soc Lap Surg* 2002;6(2):115-9.
6. Wattiez A, Canis M, Mage G, et al. Promontofixation for the treatment of prolapse. *Urol Clin N Amer* 2001;28:151-7.
7. Richardson AC. The anatomic defects in rectocele and enterocele. *J Pelvic Surg* 1995;1:214-21.
8. Miklos JR, Kohli N, Lucente V, Saye WB. Site-specific fascial defects in the diagnosis and surgical management of enterocele. *Am J Obstet Gynecol* 1998;179:1418-23.
9. Brizzolara S, Pillai-Allen A. Risk of Mesh erosion with sacral colpopexy and concurrent hysterectomy. *Obstet Gynecol* 2003;102(2):306-10.