

# Laparoscopic Pelvic Floor Repair

## Part I – Pelvic Anatomy

Robert D. Moore DO\*, John R. Miklos MD\*, Neeraj Kohli MD\*\*

Urogynaecology & Reconstructive Pelvic Surgery, \*Atlanta Urogynaecology Associates, Atlanta GA; \*\*Harvard Medical School, Cambridge MA.

### INTRODUCTION:

The anatomy, pathophysiology, and treatment of pelvic organ prolapse has significantly evolved over the last decade with increasing understanding of anatomy and development of minimally invasive surgical procedures. Although support for the pelvic viscera, the vagina, and neighboring structures involves a complex interplay between muscles, fascia, nerve supply, and appropriate anatomic orientation, the endopelvic fascia and pelvic floor muscles provide most of the support function in the female pelvis. Laparoscopic reconstructive pelvic surgery requires a thorough knowledge of pelvic floor anatomy and its supportive components before repair of defective anatomy is attempted. This review reviews contemporary concepts in pelvic support anatomy, describes the various laparoscopic surgical techniques currently available for reconstructive pelvic surgery, and summarizes currently published results of laparoscopic reconstructive pelvic surgery.

### ANATOMY OF PELVIC SUPPORT

#### Endopelvic Fascia

To understand the pelvic support system of the female pelvic organs, it is useful to subdivide the pelvic support system into 3 axes: 1) the upper vertical axis, 2) the midhorizontal axis, and 3) the lower vertical axis. The endopelvic fascia – a network of connective tissue and smooth muscle – constitutes the physical matrix which envelops the pelvic viscera and maintains the integrity of the axes supporting the bladder, urethra, uterus, vagina, and rectum in their respective anatomic relationships.

DeLancey further describes the 3 levels of support axes as follows: level 1 – superior suspension of the vagina to the cardinal-uterosacral complex; level 2 – lateral attachment of the upper 2/3 of the vagina; and level 3 – distal fusion of the

vagina into the urogenital diaphragm and perineal body.<sup>1</sup> In this support system, the endopelvic fascia system is thought to be continuous, extending from the origin of the cardinal-uterosacral complex to the urogenital diaphragm, providing structural support to the vagina and adjacent organs. (Figure 1)

#### Level 1 - Apical Support

The cardinal-uterosacral complex provides apical support by suspending the uterus and upper one third of the vagina to the bony sacrum. This complex can be described as 2 separate entities: the cardinal ligament and the uterosacral ligament. The cardinal ligament is a fascial sheath of collagen that envelops the internal iliac vessels and then continues along the uterine artery, merging into the visceral capsule of the cervix, lower uterine segment and upper vagina. The uterosacral ligament is denser and more prominent than the cardinal ligament. Collagen fibers of the uterosacral ligament fuse distally with the visceral fascia over the cervix, lower uterine segment, and upper vagina, forming the pericervical ring; proximally these fibers end at the presacral fascia overlying the second, third, and fourth sacral vertebrae. This complex appears to be the most supportive structure of the uterus and upper 1/3 of the vagina. Disruption of the cardinal-uterosacral complex may result in uterine descensus or vaginal vault (apex) prolapse. (Figure 2) Likewise, the most common cause of vaginal vault prolapse is previous hysterectomy with failure to adequately reattach the cardinal-uterosacral complex to the pubocervical fascia and rectovaginal fascia at the vaginal cuff intraoperatively. (Figure 3)

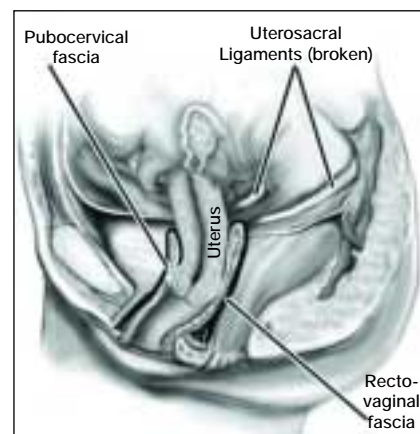


Figure 2. Uterine prolapse – begins with breaking or cutting uterosacral ligaments.

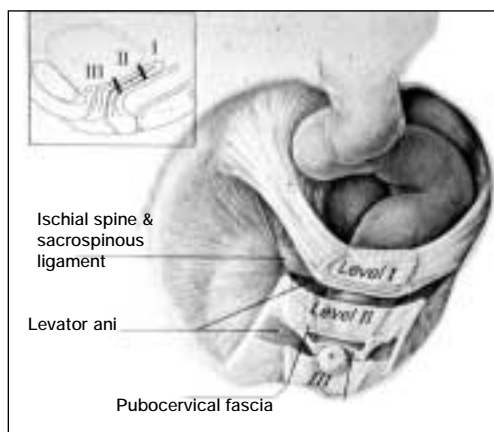
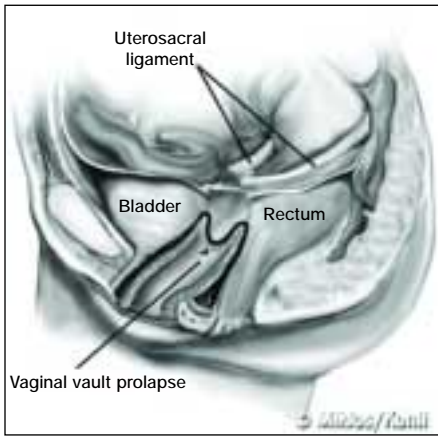


Figure 1. Level 1 (apical suspension) and level 2 (lateral attachment). Level 1 – paracolpium suspends the vagina apex from the lateral pelvic sidewall via the uterosacral-cardinal complex. Level 2 – the anterior vaginal wall is attached laterally to arcus teninous fascia pelvis and the posterior vaginal wall is attached laterally to the fascia overlying the levator ani muscle.

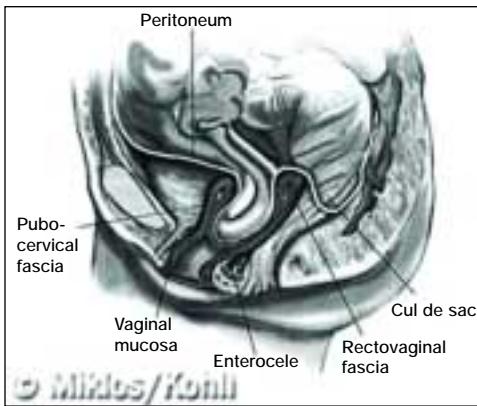
DeLancey further describes the 3 levels of support axes as follows: level 1 – superior suspension of the vagina to the cardinal-uterosacral complex; level 2 – lateral attachment of the upper 2/3 of the vagina; and level 3 – distal fusion of the

An enterocele is defined as a pelvic floor hernia where the parietal peritoneum comes into direct contact with the vaginal epithelium with no intervening fascia.<sup>2,3</sup> In normal pelvic supportive anatomy, the anterior pubocervical fascia, posterior rectovaginal fascia, cardinal-uterosacral ligaments and paracolpial fibers all converge, or fuse to form the pericervical



**Figure 3. Vaginal vault prolapse – the apex of the vagina is prolapsed due to the lack of uterosacral ligaments attachment.**

ruption of the fusion of the proximal margins of the pubocervical and rectovaginal fascia. (Figure 4) Although vaginal mucosa may cover this defect, it is not supportive, which greatly increases the likelihood that an enterocele will eventually develop within the vaginal cavity.

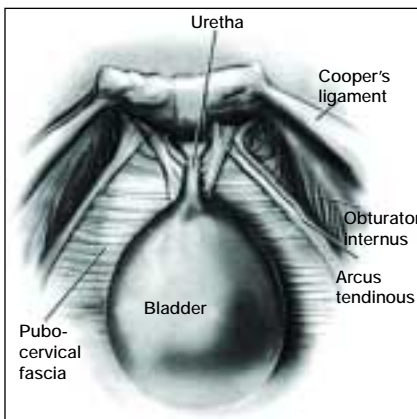


**Figure 4. Enterocele – is defined as peritoneum in direct contact with vaginal epithelium with no intervening fascia. Note the difference between vault prolapse in figure 3 and enterocele here.**

mic configuration of the cul-de-sac have been implicated in the development of the enterocele, it has never been proven to be the primary etiology.

### Level 2—Lateral Support

Level 2 provides horizontal support to the bladder, upper two thirds of the vagina, and rectum. Additionally, the vaginal wall itself has inherent support because of its fibromuscular composition, which is often referred to as “fascia”. Anterior support of the vaginal wall is provided by the pubocervical fascia, and posterior support is provided by the rectovaginal fascia. The pubocervical fascia, found between the bladder and the vaginal epithelium, attaches laterally to the arcus tendineus, also referred to as “the white line”. (Figure 5) The white line is a



**Figure 5. Space of Retzius – normal anatomy.**

ring. The integrity and continuity of these supportive tissues can be compromised in patients who have had a complete hysterectomy as previously described.<sup>4-6</sup> An enterocele is likely to be directly related to a dis-

ruption of the fusion of the proximal margins of the pubocervical and rectovaginal fascia. (Figure 4) Although vaginal mucosa may cover this defect, it is not supportive, which greatly increases the likelihood that an enterocele will eventually develop within the vaginal cavity.

Though it is possible to have an enterocele without concurrent vaginal vault prolapse, the two defects usually occur concomitantly. Although the depth and overall anat-

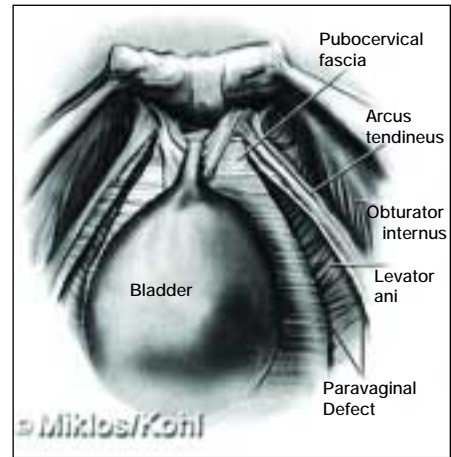
omy configuration of the cul-de-sac have been implicated in the development of the enterocele, it has never been proven to be the primary etiology.

linear thickening of the parietal fascia overlying the levator ani muscles and can be traced along its course, starting at its origin at the ischial spine, along the pelvic sidewall (obturator internus muscle) to its insertion into the pubic bone. A breach in the integrity of the pubocervical fascia or a defect in its lateral attachment at the white line can result in an anterior vaginal wall prolapse known as a cystocele, urethrocele or a cystourethrocele. (Figure 6)

Posteriorly, the rectovaginal septum, found between the vaginal epithelium and the rectum, attaches laterally to the fascia over the levator ani muscles. The rectovaginal septum lies between the vaginal epithelium and rectum, suspended superiorly by the cardinal-uterosacral complex and laterally attached to the fascia of iliococcygeal muscle and distally fused to the perineal body. This intact rectovaginal septum is the support system of the posterior vaginal wall and helps maintain the rectum in its posterior position. A breach in the integrity of the rectovaginal septum or a defect in its lateral attachment to the iliococcygeal muscles often results in development of a rectocele. (Figure 7)

Level 3 – Distal Support

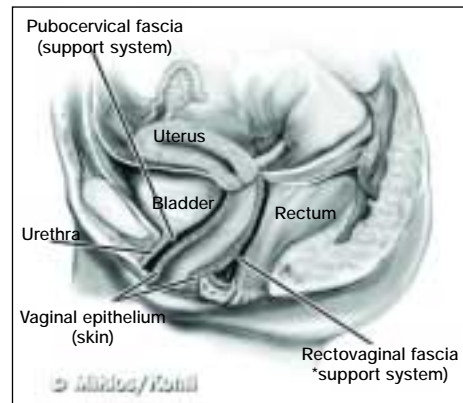
The vagina and its support structures of pubocervical and rectovaginal septum traverse the urogenital hiatus to distally fuse into the parietal fascia of the pubococcygeal and puborectal muscles and the perineal membrane. The rectovaginal septum fuses to the perineal body and the pubocervical fascia fuses to the perineal membrane of the urogenital triangle, which subsequently fuses to the pubic bone.



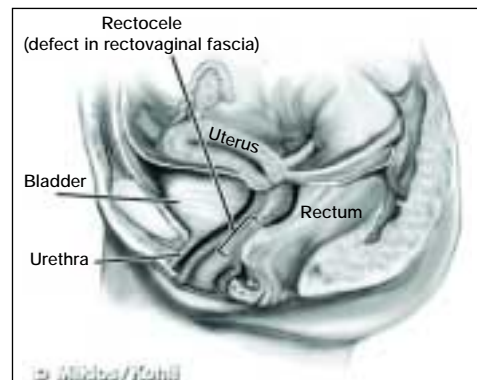
**Figure 6. Paravaginal defects: lateral vaginal wall defects result in cystourethrocele as seen from the space of Retzius.**

### Level 3 – Distal Support

The vagina and its support structures of pubocervical and rectovaginal septum traverse the urogenital hiatus to distally fuse into the parietal fascia of the pubococcygeal and puborectal muscles and the perineal membrane. The rectovaginal septum fuses to the perineal body and the pubocervical fascia fuses to the perineal membrane of the urogenital triangle, which subsequently fuses to the pubic bone.



**Figure 7a. Rectovaginal fascia – normal anatomy.**



**Figure 7b. Rectocele – caused by a defect in the rectovaginal fascia.**

• To be continued in next issue