

Sciatic Hernia As a Cause of Chronic Pelvic Pain in Women

JOHN R. MIKLOS, MD, MICHAEL J. O'REILLY, MD, AND WILLIAM B. SAYE, MD

Objective: To review experience with 20 women treated for sciatic hernia between 1993 and 1997.

Methods: Patients with chronic pelvic pain and sciatic hernias, identified retrospectively from chart review, were seen during a 46-month period that covered the surgical experience at our institution and included approximately 1100 cases. The median length of follow-up was 13 months (range 3–36).

Results: Sciatic hernia was diagnosed in 20 white women with chronic pelvic pain and was treated using laparoscopy. In 14 cases the hernias were right sided, in five they were left sided, and in one they were bilateral. All sciatic hernias contained the ipsilateral ovary alone or with its fallopian tube. All 20 patients reported symptomatic relief at follow-up.

Conclusion: Sciatic hernia is a cause of chronic pelvic pain and should be considered in the differential diagnosis. (*Obstet Gynecol* 1998;91:998–1001. © 1998 by The American College of Obstetricians and Gynecologists.)

Sciatic hernia also is known as sacrosiatic hernia, ischiatic hernia, gluteal hernia, hernia incisurae ischiadicae, and ischiocele.¹ Despite its being a well-defined anatomic defect, first described by Papen in 1750 and observed and recorded by Verdier in 1753,² we found only a few articles in the literature concerning this pelvic floor hernia.^{2–17} A computerized search of English-language abstracts in MEDLINE for the period 1966–1996 (keywords: “pelvic floor hernia” and “sciatic hernia”) and a review of the bibliographies of the relevant articles generated by the search revealed a total of 57 cases of sciatic hernia.

The sciatic notch on the inferior margin of the pelvis is transformed into the greater and lesser sciatic foramina by the sacrospinous and sacrotuberous ligaments, respectively. The greater sciatic foramen is subdivided by the piriform muscle, which traverses the space. Abnormal development or atrophy of the piriform muscle

allows space to develop between adjacent muscles and appears to predispose one to sciatic hernia.^{1,13,17} Sciatic hernias may emerge through either the supra- or infra-piriform spaces or through the lesser sciatic foramen (ie, subspinous) (Figures 1 and 2). The internal introitus lies in the ovarian fossa, at the base of the broad ligament and lateral to the uterosacral ligament (Figure 3). The sac may contain small bowel,^{1,13,15} urinary bladder,¹⁷ ovary,¹ ureters,^{3,7–10} Meckel diverticulum,¹⁸ or colon.^{15,19}

Clinically, sciatic hernias present usually with various pain patterns originating in the pelvis and sometimes radiating to the buttocks and posterior thigh. Intestinal or ureteral obstruction with or without strangulation is sometimes responsible for the first symptoms and the diagnosis usually is established during exploratory laparotomy. Because of the large gluteal muscle overlying the sciatic foramen and the piriform muscle, sciatic hernias are rarely evident on physical examination. We reviewed the records of 20 women with chronic pelvic pain due to sciatic hernias diagnosed with laparoscopy and subsequently repaired.

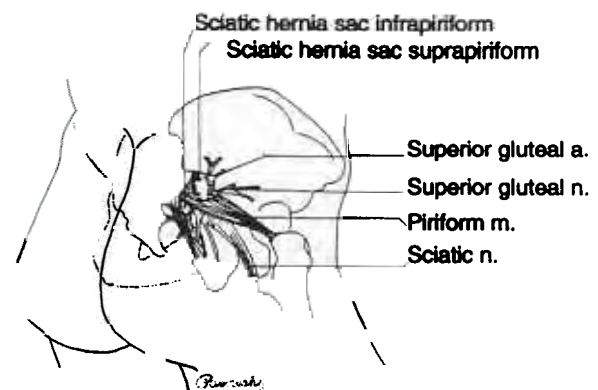


Figure 1. Posterior view of superior and inferior piriform sciatic hernias. a = artery; n = nerve; m = muscle.

From the Advanced Laparoscopy Training Center, Marietta Medical Center, Marietta, Georgia.

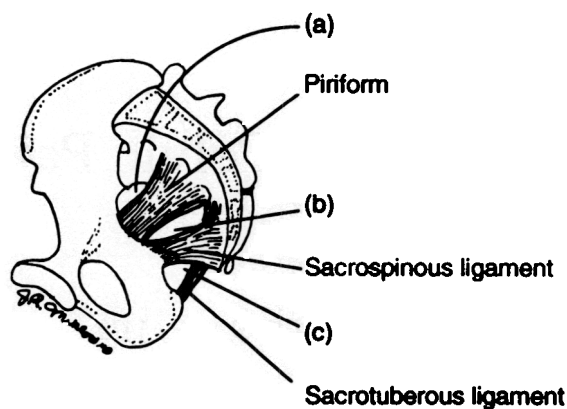


Figure 2. Sites of potential hernias through the sciatic foramina (anterior view). a = suprapiriform; b = infrapiriform; c = subspinous.

Patients and Methods

Patients with chronic pelvic pain and sciatic hernias were identified retrospectively from chart review, which covered the surgical experience at our institution during a 46-month period and included approximately 1100 cases. Patients identified as having sciatic hernia repair were analyzed for age, race, parity, weight, physical signs, symptoms, hernia content, and the side of pelvis affected. All patients reviewed had a diagnosis of chronic pelvic pain, defined as nonspecific pelvic pain of longer than 6 months' duration that was not relieved by medical therapy. Preoperative evaluation included a history and physical examination, complete blood count, and urinalysis. Pelvic ultrasounds were ordered if abnormal pelvic masses were noted on physical examination or if the examination was inconclusive. A bowel preparation was given, consisting of a full liquid diet 48 hours before scheduled surgery and a clear liquid diet and one bottle of magnesium citrate 1 day before surgery. A single dose of cephalosporin was given intravenously before the operation. Laparoscopy

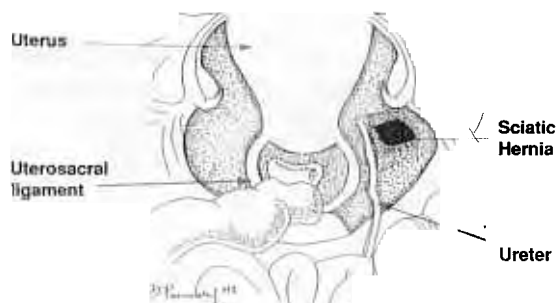


Figure 3. Internal introitus of a sciatic hernia with a medially displaced ureter.

was performed under general anesthesia with the patient in the lithotomy position. In all cases, at least two accessory ports (12 mm and 5 mm) were used for instrument access.

Systematic diagnostic laparoscopy was performed by inspecting the liver, gallbladder, appendix, and colon and running the small bowel. The pelvis was inspected for adhesions, endometriosis, and hernias. When a sciatic hernia was identified, its contents were reduced. The peritoneum overlying the sciatic hernia was elevated and transected transversely with endoscopic scissors. Using blunt dissection the obturator internus and coccygeus muscles were identified. A 6.0 × 12.5-cm piece of Surgi-Pro Mesh (US Surgical, Norwalk, CT) was folded and placed into the space created by the atrophic piriform muscle. A second piece of mesh was trimmed to the size of the peritoneal defect and placed over the folded mesh. This overlying mesh was secured to the obturator internus fascia laterally and the coccygeus medially with a 4.9-mm multifire hernia stapler (US Surgical). The peritoneum overlying the mesh was closed using a hernia stapler.

Patients were admitted to the hospital and discharged in less than 24 hours. They were asked to return for follow-up at 6 weeks, 3 months, and annually thereafter. The primary surgeon evaluated all patients for pain pre- and postoperatively.

Results

All records noted preoperative complaints of chronic pelvic pain, and seven records also included ipsilateral posterior thigh or buttocks pain or both. No patients had signs of sciatic hernia on physical examination. Fourteen women had right-sided sciatic hernias, five left-sided sciatic hernias, and one bilateral hernias. All sciatic hernias contained the ipsilateral ovary alone or with its fallopian tube. Six patients also had a diagnosis of other causes of pelvic pain: endometriosis ($n = 1$), adhesions ($n = 2$), endometriosis and adhesions ($n = 1$), indirect inguinal hernia ($n = 1$), and indirect inguinal and umbilical hernia ($n = 1$). Fourteen patients had a total of 17 previous diagnostic laparoscopies by other surgeons for pelvic pain.

The mean age was 34.3 years (range 23–58), mean gravidity 1.0 (range 0–3), mean parity 1.0 (range 0–2), and mean weight 60 kg (range 49–75). No patients sustained intraoperative or postoperative complications. Preoperative and follow-up examinations were performed by the surgeon. All 20 patients reported immediate pain relief at their initial 3-month follow-up evaluation; 14 described complete pain relief, and six noted improvement over preoperative symptoms with a median length of follow-up of 13 months (range 3–36).

Discussion

In his 1946 review of sciatic hernia, the most comprehensive to date, Watson¹ uncovered only 35 documented cases since 1750. His review suggests sciatic hernias occur only slightly more often in women than in men. A computerized search of English-language abstracts in MEDLINE for the period 1966–1996 (keywords: “pelvic floor hernia” and “sciatic hernia”) and a review of the bibliographies of the relevant articles published after 1946 revealed a total of 22 patients with sciatic hernias.^{2–17} Of the 18 patients whose gender was identified, 15 were female. When the 20 patients described in the current article are taken into account, the findings suggest clearly that sciatic hernias occur more frequently in women.

Sciatic hernia is a well-defined anatomic defect that is the direct result of piriform muscle atrophy. Thorough knowledge of pelvic anatomy is essential in understanding this concept. During laparoscopy, anatomic orientation can be achieved by palpating the insertion of sacrospinous-coccygeal complex at the ischial spine. Immediately superior to this complex lies the piriform muscle. If at this level the peritoneum sags and forms an introital ring, it is apparent that there is a reduction in pelvic floor muscle posterior to this area of peritoneum. The muscle at this level is the piriform muscle.

Sciatic hernias are unusual findings and often present the physician with a diagnostic dilemma. Patients rarely exhibit signs (ie, bulge, protrusion, or saccule) because the hernia sac is relatively small compared with the large overlying gluteus maximus muscle. Most patients with pelvic hernias (ie, inguinal, obturator, femoral) complain of pain, pressure, or a pulling sensation. Patients with sciatic hernias commonly present with symptoms of abdominal, pelvic, lower back, or posterior thigh pain. All of our patients described some form of chronic pelvic, thigh, or buttock pain and subsequently were subjected to diagnostic laparoscopy. Because six of our patients had other potential causes of pelvic pain, we cannot attribute the pain in those patients to sciatic hernias alone. We do recognize that a standardized pain assessment would have been most beneficial in determining surgical outcome.

Most commonly, the hernia sac contains small bowel, ovary, or ureter; other documented hernia sac contents include bladder, Meckel diverticulum, and colon. All of our patients' hernia sacs contained an ipsilateral ovary alone or with its fallopian tube. None of our patients were found to have bowel or ureter in the hernia sac. In all cases, the ureter was found to be displaced medial to the hernia sac. This may occur because the ovary displaces the ureter medially when it settles into the space created by the atrophic piriform muscle.

Although oblique x-ray studies, computed tomography, herniography, enterography, intravenous pyelography, and cystography have been helpful in the diagnosis of sciatic hernias, they have never been proven to be definitive. Consistent with other types of pelvic hernias, sciatic hernias have been diagnosed most commonly and treated definitively during surgery. Specifically, most sciatic hernia repairs use either a transgluteal or transperitoneal approach. Closure of the defect by ligation of the sac and suturing of the piriform muscle to the periosteum of the sciatic notch has resulted in frequent recurrence of the hernia.² Alternatively, synthetic mesh plugs,¹⁹ stainless steel wire mesh,² fascia graft and tantalum mesh,⁶ and flaps of the piriform and gluteal muscles⁵ have been used to close sciatic hernias. We chose to repair the sciatic hernia with a synthetic mesh plug, using laparoscopy for our transperitoneal approach. The synthetic mesh is retroperitonealized in an attempt to reduce intra-abdominal adhesions. Laparoscopy aids in the diagnosis of hernias by providing excellent visualization of the pelvis. Intra-abdominal pressure, created by insufflation, may be helpful in the detection of sciatic hernia through stretching the peritoneum to its limit of support (eg, bone or muscle). However, in all of our cases, the hernia was filled with the ipsilateral ovary and/or fallopian tube, leaving little room for distention of the peritoneum by intra-abdominal carbon dioxide.

Considering the number of journal articles written each year on gynecologic pelvic pain, it is surprising that not one of the sciatic hernia articles found in our MEDLINE search was in a gynecology journal. Laparoscopy may aid in the definitive diagnosis and treatment of all hernias only if the surgeon has a thorough knowledge of pelvic anatomy and its potential defects. We propose sciatic hernia as a differential in the diagnosis of pelvic pain in women.

References

1. Watson LF. *Hernia: Anatomy, etiology, symptoms diagnosis, differential diagnosis, prognosis and treatment*. 3rd ed. St. Louis: Mosby, 1948.
2. Sadek HM, Kiss DR, Vanconcelos E. Sciatic hernia caused by a neurofibroma. Surgical repair with stainless steel wire mesh. *Int Surg* 1970;54:135–41.
3. Lindbom A. Unusual ureteral obstruction by herniation of ureter into sciatic foramen: Report of a case. *Acta Radiol* 1947;28:225–6.
4. Beck WC, Baurys W, Brochu J, Morton WA. Herniation of the ureter into the sciatic foramen. *JAMA* 1952;149:441–2.
5. Henegar GC. Sciatic notch hernia: Report of a case and description of a new operative approach. *Arch Surg* 1952;64:399–400.
6. Gaffney LB, Schanno JF. Sciatic hernia: A case of congenital occurrence. *Am J Surg* 1958;95:974–5.
7. Franken BA Jr, Smith EE. Sciatic hernia: Report of three cases including two with bilateral ureteral involvement. *Am J Roentgenol Radium Ther Nucl Med* 1969;107:791–5.

8. Rothchild TP. Ureteral hernia. Report of a case of herniation of the ureter into the sciatic foramen. *Arch Surg* 1969;98:96-8.
9. Bohnert WW. Ureteral sciatic hernias: Case report of an infant with bilateral ureteral herniation into the sciatic foramina. *J Urol* 1971; 106:142-3.
10. Lebowitz RL. Ureteral sciatic hernia. *Pediatr Radiol* 1973;1:178-82.
11. Spring DB, Vandeman F, Watson A. Computer tomographic demonstration of ureterosciatic hernia. *AJR Am J Roentgenol* 1983;141:579-80.
12. Oyen R, Gielen J, Baert L. CT demonstration of a ureterosciatic hernia. *Urol Radiol* 1987;9:174-6.
13. Ghahremani GG, Michael AS. Sciatic hernia with incarcerated ileum: CT and radiographic diagnosis. *Gastrointest Radiol* 1991; 16:120-2.
14. Attah M, Jibril JA, Yakubu A, Kalayi GD, Nmadu PT. Congenital sciatic hernia. *J Pediatr Surg* 1992;27:1603-4.
15. Ivanov NT, Losanoff JE, Kjossev KT. Recurrent sciatic hernia treated by prosthetic mesh reinforcement of the pelvic floor. *Br J Surg* 1994;81:447.
16. Epner SL, Lautin EM. Case report: Intermittent sciatic herniation of the ureter. *Clin Radiol* 1994;49:832-3.
17. Hayashi N, Suwa T, Kimura F, Okuno A, Ishizuka M, Kakizaki S, et al. Radiographic diagnosis and surgical repair of a sciatic hernia: Report of a case. *Jpn J Surg* 1995;25:1066-8.
18. Brodnax JW. Sciatic hernia: Report of a case of herniation of Meckel's diverticulum through the greater sciatic foramen. *JAMA* 1924;82:440-2.
19. Black S. Sciatic hernia. In: Nyhus LM, Condon RE, eds. *Hernia*. Philadelphia: JB Lippincott, 1989:432-41.

Address reprint requests to:

John R. Miklos, MD
Urogynecology
308 Maxwell Road
Suite 100
Alpharetta, GA 30004

Received June 30, 1997.

Received in revised form February 3, 1998.

Accepted February 13, 1998.

Copyright © 1998 by The American College of Obstetricians and Gynecologists. Published by Elsevier Science Inc.