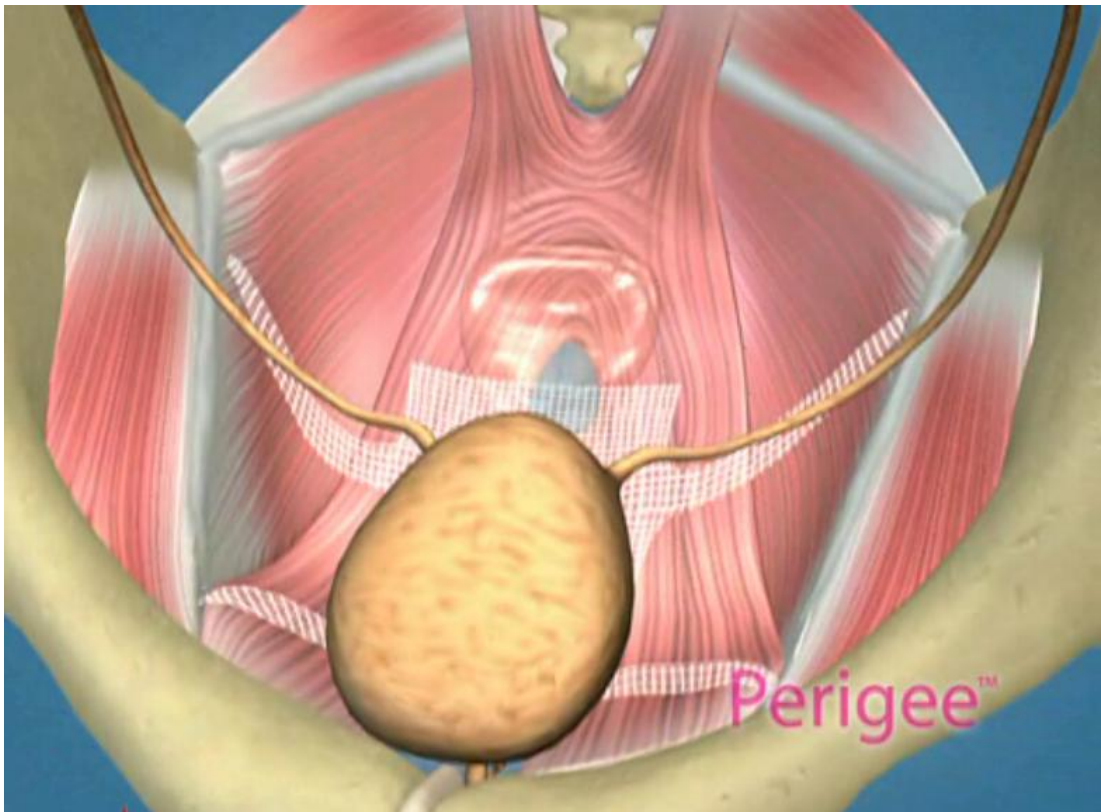


**Transobturator Approach For Cystocele
Repair
With Anterior Wall Mesh**



Introduction/Background

Anterior vaginal wall relaxation (cystocele) is one of the most commonly diagnosed forms of pelvic organ prolapse in women. More than 200,000 cystocele repairs are completed yearly, however to date the procedures that are completed do not provide very high cure rates and/or poor anatomic outcomes. Successful treatment of anterior vaginal wall prolapse remains one of the most challenging aspects of pelvic reconstructive surgery we face. We have developed very good procedures that provide excellent support for the posterior wall (ie rectoceles) and the apex of the vagina (ie vaginal vault prolapse) and reproduce normal anatomy. We were one of the first centers in the country to utilize grafts in rectocele repairs and have seen improved cure rates to over 90% with minimal complications. It has been known for many years that abdominal sacralcolpopexy with placement of a mesh graft at the top of the vagina for vaginal vault prolapse is the most successful procedure in the literature. We have made advancements with this procedure as well in being able to offer our patients a laparoscopic minimally invasive approach for sacralcolpopexy, with the same excellent cure rates (>92%) and with hospital stays typically less than 24 hours and reduced complications. However the anterior wall has been one of the most difficult compartments in the vagina to get good anatomic results and high cure rates with traditional repairs and at the same time not cause sexual dysfunction, pain with intercourse, voiding dysfunction (ie incontinence or urgency/frequency syndrome), or a shortened or scarred down vagina.

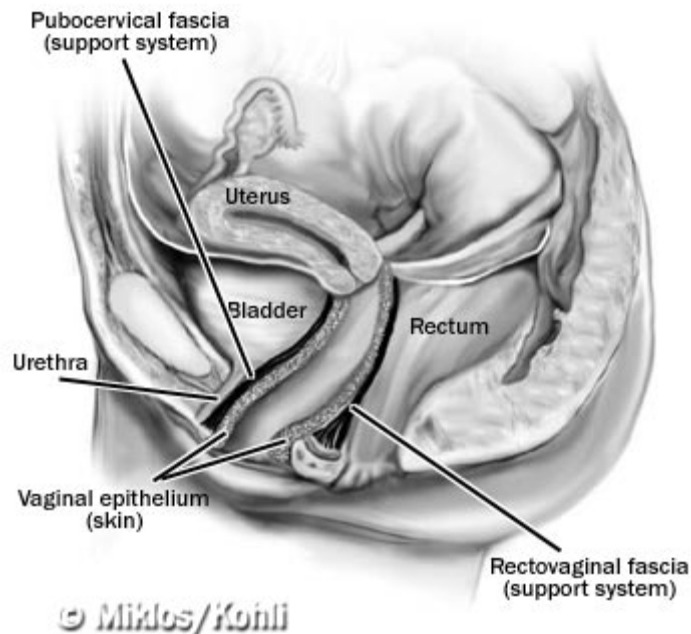


Figure 1. Normal anatomic support of the pelvis and the bladder. Note the layer of pubocervical fascia that supports under the bladder and keeps it in proper position.

Anterior vaginal wall reconstruction concentrates on the surgical repair of cystocele, which in essence is a hernia that occurs when the bladder bulges down into the vagina due to attenuation or site-specific defect of the pubocervical fascia. This fascia is the layer under the vaginal skin that provides support to the bladder and keeps it in its normal anatomic position in the pelvis. It stretches from one side of the pelvis to the other (from what is called the white line or the arcus) and provides a floor of support that the bladder sits on. If this fascia has a tear in the middle of it (midline defect), is torn away from the pelvic sidewalls (paravaginal defects) or is just generally stretched out or attenuated beyond its capacity to recover, the result is that the bladder sags down or bulges out of the vagina with a resultant cystocele (Fig 2).

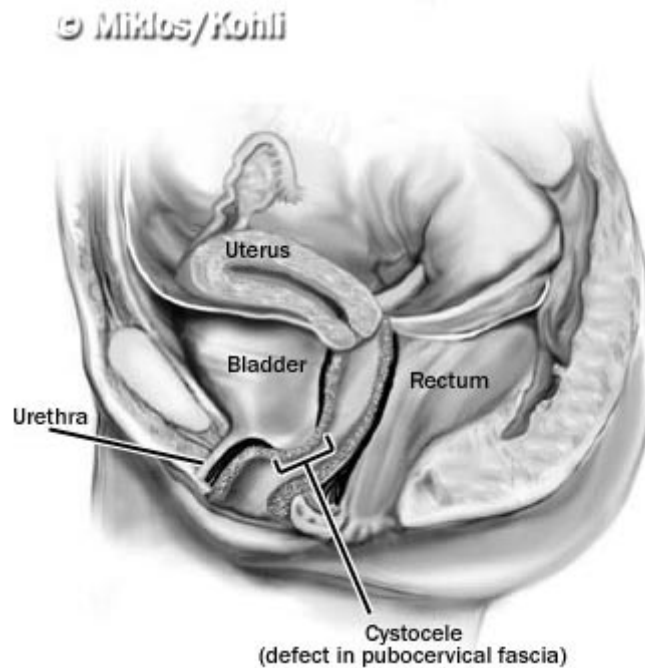


Figure 2. Cystocele. Defect (hernia) in the supportive layer (pubocervical fascia) causing the bladder to drop into the vagina and creating a bulge (cystocele) that may eventually protrude outside the vaginal opening.

Traditionally, the cystocele has been repaired with what is called an Anterior Colporrhaphy (or simply Anterior Repair) which requires plication of the fascia from side to side from the bladder neck up to the top of the vagina. It is still today the most commonly performed procedure to treat cystoceles, despite failure rates in the literature typically in the range of 30-50%. It is one of the oldest procedures ever described for prolapse, and despite its poor cure rates, it continues to be performed by most gynecologists and urologists to treat cystoceles. In fact many patients are even told by their physicians to wait to get the procedure done until they are older as they will just have to get it done again at some point because eventually they will fail! In addition to having high failure rates, typically the anatomic outcomes are not optimal either as once the tissues are plicated together in the midline, the vagina can be constricted and then even further shortened as the surgeon cuts off what they call excess vaginal skin. This

very commonly can cause pain with intercourse or the inability to have intercourse if the vagina is too constricted or shortened. It may reduce the bulge, however this is not a true repair, it is just a compensatory procedure that is plicating weakened tissue to weakened tissue that most likely will eventually tear or stretch out again, subjected to the same forces that caused the prolapse initially. Additionally, it is not uncommon to have voiding dysfunction following this tightening of tissue right under the bladder neck. Another theory of why these repairs fail is that if the patient actually has paravaginal defects (ie the tears are actually out laterally and the support has pulled away from the pelvic sidewalls), then the surgeon is actually pulling the good fascia farther from the sidewalls by plicating in the midline.

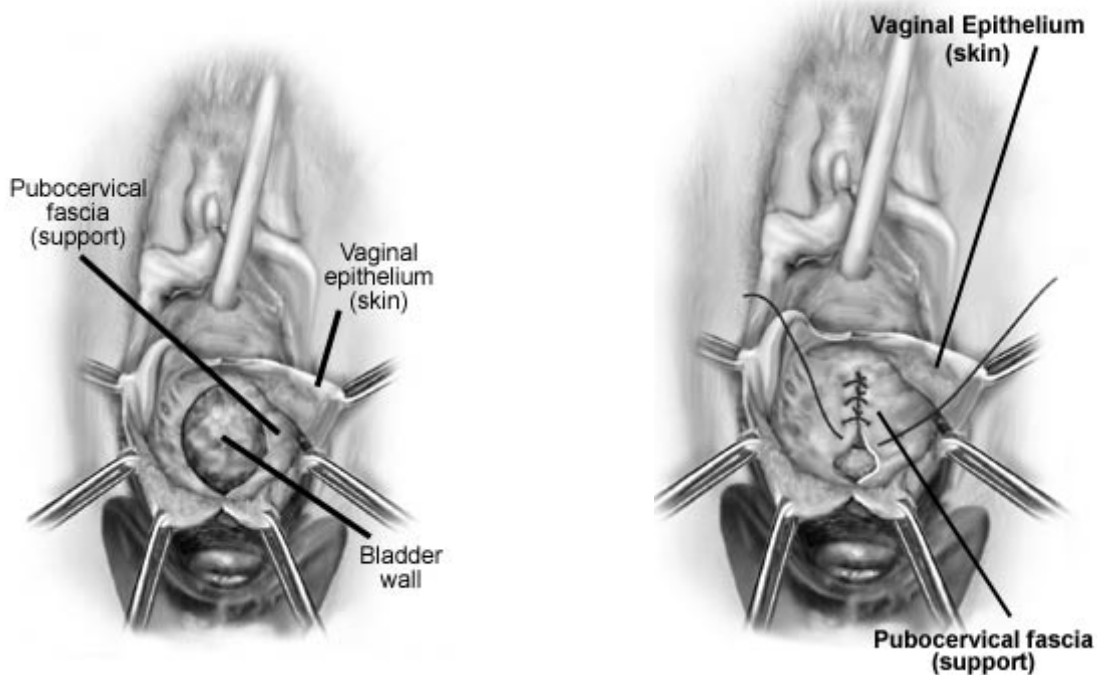


Figure 3. Traditional Anterior Repair. The tissue under the bladder is plicated and pulled together in the midline, thus reducing the bulge. Following the reduction, excess vaginal skin is then cut off which can create a shortened or constricted vagina.

Over the past 15-20 years, Richardson and others have popularized the paravaginal defect repair for cystoceles. This repair involves locating the lateral tears of the pubocervical fascia away from the pelvic sidewalls and re-creating normal anatomy by actually repairing the tears, thus bringing the bladder up into its normal anatomic position in the pelvis. This procedure is most commonly completed abdominally, as even the experts in the vaginal approach for paravaginal repair admit inadequate cure rates and high complication rates with high rates of bleeding and technical difficulties in performing the procedure vaginally. The surgeon actually has to tear down any remaining support out to the sidewalls prior to the repair and then try to reconnect the lateral vaginal support tissue back up to the white line through the vagina. Visibility is very poor and most “experts” in

this type of repair have abandoned the vaginal approach. We believe that the paravaginal repair completed abdominally, more specifically, laparoscopically, is the most anatomic repair of the anterior vaginal wall that is available (see our section on Laparoscopic Paravaginal Repair). Laparoscopically, we are able to visualize the defects very clearly and then actually repair the tears directly back out to the pelvic sidewall. Utilizing this approach, the vaginal wall is not incised at all (and no vaginal skin is removed) and therefore vaginal wall length and caliber are maintained, which we feel is very important for sexual function. Our laparoscopic approach offers patients a very minimally invasive approach to the repair, and in young sexually active patients is still our primary approach to cystocele repair. However, the laparoscopic approach is technically very difficult, requires advanced surgical skills and very few centers in the country are able to offer this approach, therefore an abdominal incision is required which makes the procedure much more invasive and less favorable among surgeons and patients. Additionally, although theoretically paravaginal repair would seem more effective (we feel it is certainly much more anatomic repair), it has never been proven to be more effective than traditional anterior repair. Again, even with paravaginal repair we are relying on suturing the patient's native tissue back together, and this is the tissue that failed in the first place, therefore may be the cause of recurrence in the future.




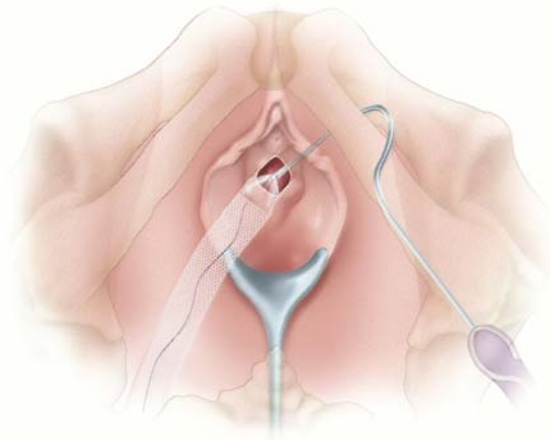
Figure 4. Paravaginal Repair completed Laparoscopically. The fascia of the anterior vaginal wall that should be keeping the bladder in place up in the pelvis is torn away from the sidewalls causing the bladder to rotate and descend down creating the bulge of the cystocele. The tears are visualized and repaired from above as depicted in the diagrams.

Graft use in Prolapse Surgery

Over the past few decades there has been growing interest and investigation in graft use for surgical correction of prolapse and incontinence. The initial work stems from the general surgery literature, where they realized many years ago that abdominal hernia repairs had much higher cure rates when a graft was used to repair the hernia. This only makes common sense, and we have recently seen more and more data supporting graft use in pelvic floor prolapse surgery. With traditional repairs (ie not using grafts to

augment our repairs) we are relying on repairs in which we are suturing weak tissue to weak tissue, under tension (which goes against all basic surgical principals!). It's no wonder that we have poor cure rates! Today, very few abdominal wall hernias are repaired without a graft and we are now seeing similar trends in prolapse surgery. We have known for many years that abdominal sacralcolpopexy has the highest cure rate for vault prolapse, and that most likely is because a graft is used and we are not relying on the patients own tissue to hold up. As stated above and in our posterior repair section, we began using grafts back in 1998 and have done much of the research and initial work in the field of graft use for rectocele repairs. We have seen a substantial increase in cure rates (>90% compared to 60% with traditional repairs) and much better anatomic outcomes. There has been work done for several years in placement of anterior vaginal wall grafts for cystoceles, however the difficulty has been in finding a minimally invasive approach to attach the grafts up higher in the vagina to the sidewall and to have a good strong attachment point and obtain anatomic restoration. We feel that grafts should be considered in patients that have had previous failed operations, older patients with poor tissue or patients with large defects or severe prolapse. Up until recently, these techniques were very invasive and fraught with high complication rates such as bleeding, bladder and/or nerve injury, graft rejection, and poor anatomic outcomes.

Transobturator Approach- New, Safer Technique



In the early 2000's, the transobturator space was initially described for the safe placement of slings to treat stress urinary incontinence. Dr Moore and Miklos were two of the first surgeons in the United States to utilize this technique and bring this new technology to the US. They have also been involved with the largest study in the world (Dr Moore is one of the principal investigators for the worldwide study and is the Principal/Lead US Investigator directing centers such as Harvard and Cleveland Clinic in the study) studying this space for the treatment of stress incontinence and have found it to be a much safer, less invasive approach than other approaches to date, with excellent cure

rates for SUI. Dr Moore just returned from Copenhagen and Montreal (2005) where he presented the results of those studies and he and Dr Miklos' research, which showed cure rates in the range of 90% for the TOT sling. The TOT sling has rapidly become one of the most common forms of treatment for stress incontinence in the world.

Advantages of Transobturator Approach

- Safer, faster, more efficient**
- Decreased risk of:**
 - Bowel Injury**
 - Bladder Injury**
 - Major Bleeding**
- No Retropubic Needle Passage**
- No Abdominal Incisions**
- More Anatomic Position of Graft**

In Dr Moore's and Miklos' initial travels to France and Italy, where they operated with the developers of these techniques for stress incontinence (ie Dargent, Mellier, Courtieau, Von Theobald and others) they also observed their work in utilizing this same space to pass needles through it, to be able to attach an anterior wall graft up high on the pelvic sidewalls in a very time efficient and minimally invasive approach to treat cystoceles. At the same time, the Australians (who developed Posterior IVS system for vault prolapse), specifically Professor AJ Rane, were also investigating this same space as a potential space to be able to reach a point on the white line up near the ischial spine to have a strong attachment point for an anterior wall graft for cystocele repair. Modifications of some of these techniques have been made to make the approach easier and safer since that point in time. After evaluating the procedure in Europe and completing many cadaver studies, Dr Moore was the first US surgeon to utilize the Perigee system (the first Transobturator system released in the US) to place an anterior wall graft for repair of cystocele. Since that point in time, he has also become the lead investigator in the United States clinical trial of the Perigee and presented (in conjunction with Dr Miklos) one of the first papers and videos in the world on the procedure at the International Urogynecology Meeting in Copenhagen in 2005. Dr Moore has worked with other world wide leaders to help develop this product in the United States and is directing other centers such as Harvard, Cleveland Clinic and others in the current US study.

Position of Mesh

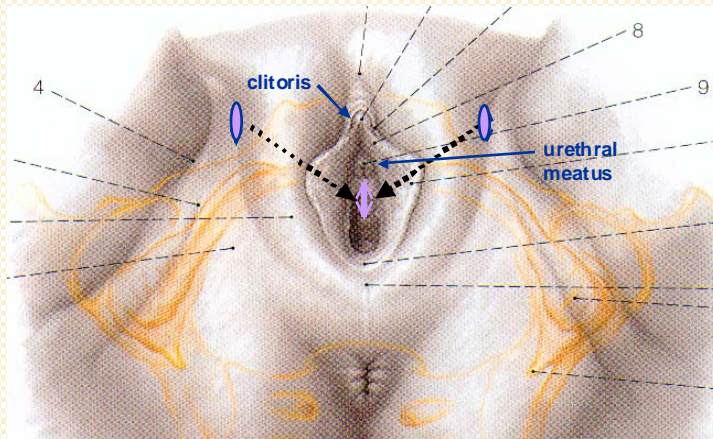
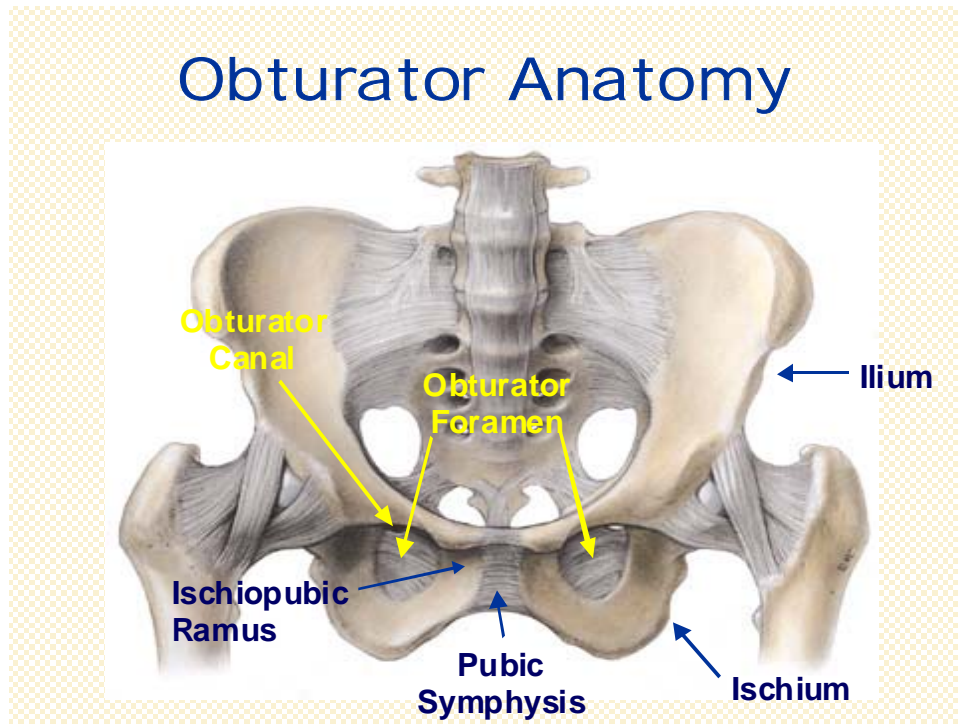


Figure . The original incisions of the TOT sling are used to attach the bladder neck portion of the graft under the bladder. One more incision is made on each side lower in the groins to pass the superior needle through the obturator space to attach the superior portion of the graft.

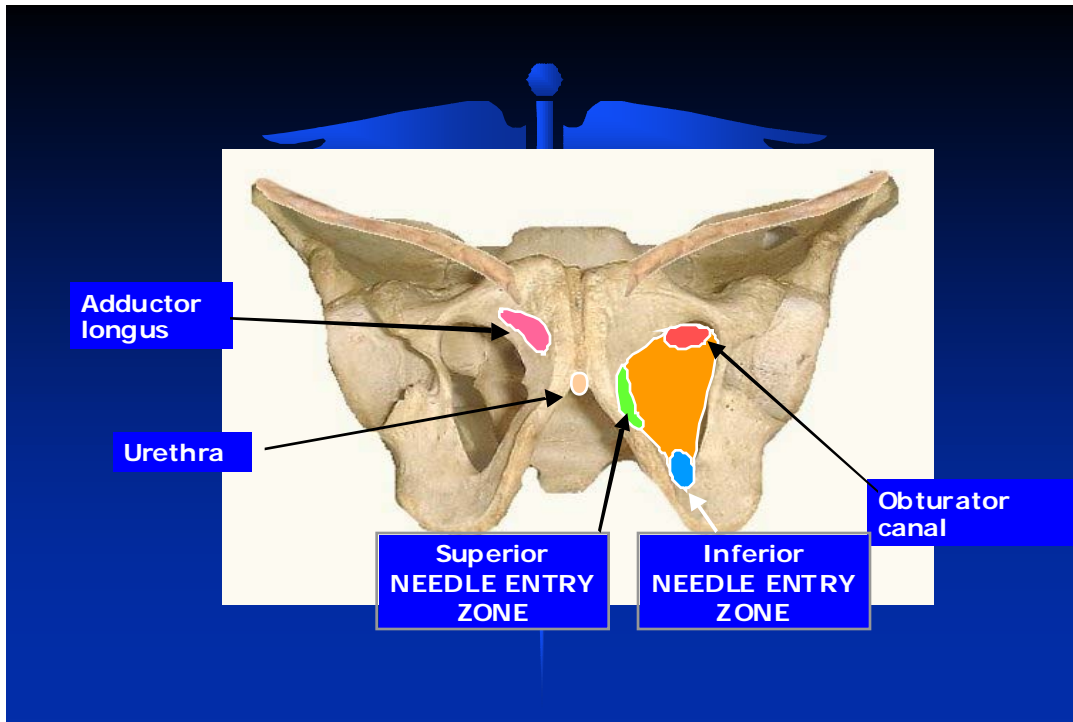
The transobturator approach to graft placement is subfascial, ie the needles or the mesh arms NEVER enter the retropubic space

Very small incisions are placed in the groins (two on each side) and a small incision is made in the vagina under the bladder, allowing the graft to be placed under the bladder in the correct position without having to pass needles blindly through the retropubic space and the abdominal wall or down to the sacrospinous ligaments. The space that the needle passes through has been extensively studied (Dr Moore and Miklos have done numerous cadaveric dissections to study the anatomy of the space) and has been found to be a very safe space to work in. There is very minimal risk of major bleeding (no major blood vessels), bowel, bladder or nerve injury. Many physicians are concerned of the route of the obturator and/or pudendal nerves, however we have completed dissections showing that if done correctly, the obturator and pudendal nerves are nowhere near the surgical tract of the needles (see anatomy below). The needle is also guided by a finger placed vaginally throughout its tract, therefore there is minimal blind passage of the needle.

Transobturator Anatomy



The obturator foramen is covered by a thick membrane called the obturator membrane. The external and internal obturator muscles cover this membrane. It is a very safe space anatomically, ie there are no major vascular or nerve structures near the ischiopubic ramus. This is the area that the needle is passed for the sling placement, as well as the needles used for anterior wall graft placement. As can be visualized by the drawing, the obturator canal is very lateral and superior to the ischiopubic ramus, this is the area that the obturator nerve and vessels transverse.

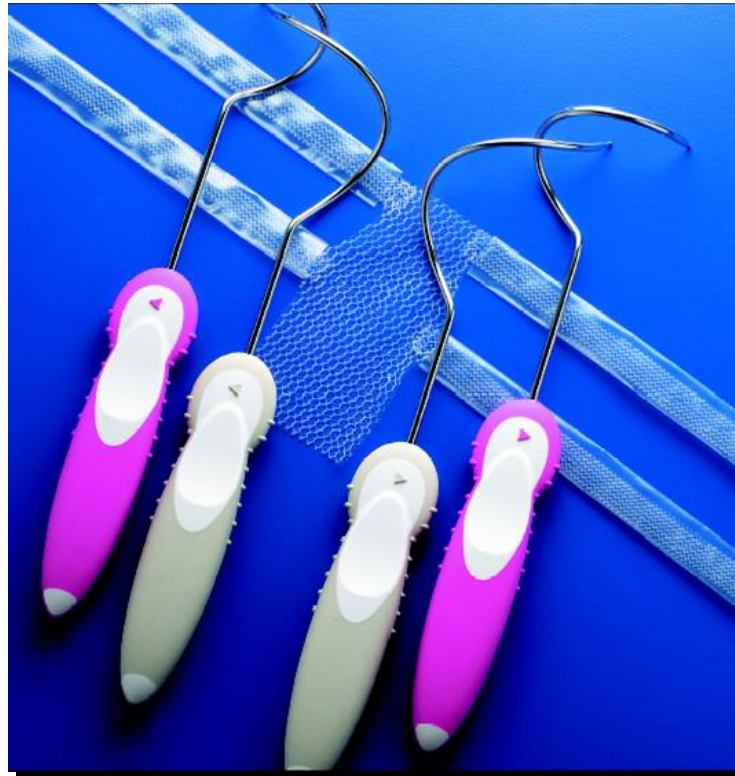

The above diagram depicts where the Perigee needles are passed for the transobturator approach for anterior graft placement under the bladder. The superior needle pass is the same exact needle and pass as for the Monarc TOT sling procedure. The inferior pass is the “new” pass and is the needle that is passed to attach the more apical arm of the graft. The inferior needle pass is safe and even further away from the obturator vessels and nerves than the superior pass. The graft has 4 arms coming off of it (2 on each side) that attaches it out lateral to the pelvic sidewalls. The graft is placed “tension-free” under the bladder, ie there is not a lot of tension on the graft and the lateral arms are not pulled “tight”.

The superior needle pass attaches the arms at the level of the bladder neck and the inferior needle pass attaches the more apical aspect of the graft up near the ischial spines (near the top of the vagina). Grafts have been used for several years for cystocele repairs, however it has always been difficult to obtain safe, strong attachments of the grafts out laterally to the sidewall. The transobturator approach allows the surgeon to pass needles through the obturator space and then the pelvic sidewalls, then pull the mesh arms back through the muscles and fascia on the sidewalls (right through the white line) for a very strong, safe attachment! Historically, attaching the graft on the sidewalls up near the top of the vagina was very technically difficult and invasive, however this is also the most important area to have a strong attachment.

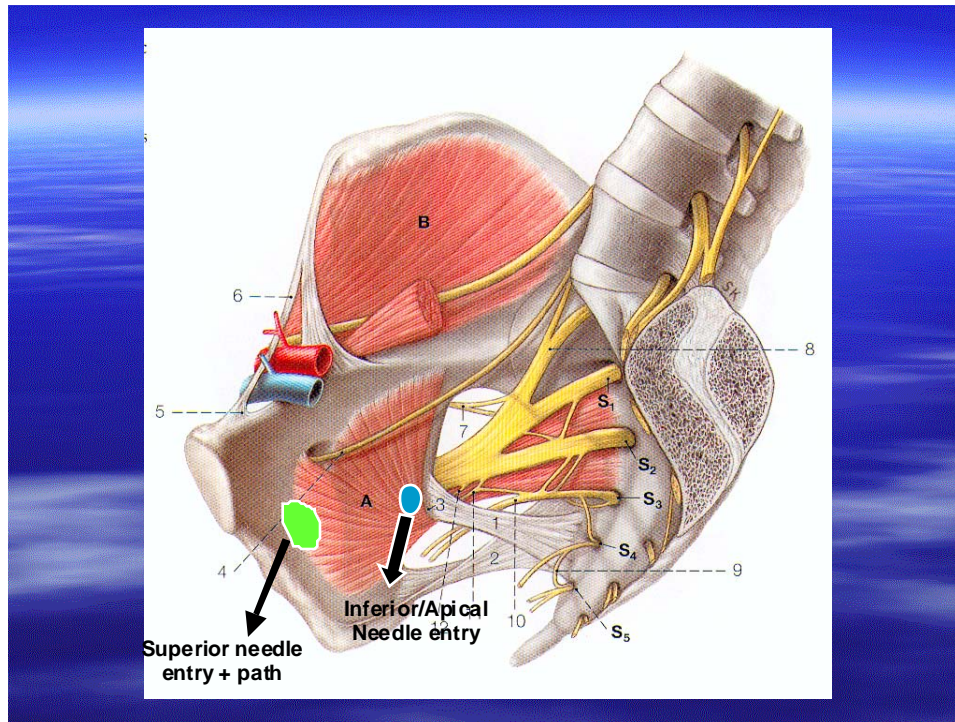
The transobturator approach allows the surgeon to get a strong, safe attachment of the graft with a minimally invasive, safe approach. A small incision is made vaginally and the vaginal epithelium dissected away from the bladder, just as if the surgeon was doing a traditional anterior repair without a graft. The dissection is very simple and safe. The

needles are passed through very small incisions in the groins (see surgical technique below), through the obturator membrane and into the obturator space. At this time the needles can be palpated directly by the surgeon with a finger placed in the vaginal dissection and they are guided directly by the surgeon to the exact location on the pelvic sidewall that he/she wants the graft to be attached. This helps protect the bladder and urethra from potential injury and thus avoids a “blind” needle passage. The needles are then brought through the pelvic sidewall (obturator and levator muscle and fascia), the arms attached, and they are brought back out their respective incisions. Once all needles are passed, the arms adjust the graft into place.



Perigee System for Transobturator Cystocele Repair: The picture depicts the graft used for anterior wall repair. The graft is 5cm wide by 10cm long. The apical portion of the graft has a tail on it that can be cut to fit the length of the patient's vagina. It has 4 arms coming off laterally that are attached to the pelvic sidewall with needles passed through the transobturator space. The pink needles are the superior needles and are used to attach the bladder neck arms (same needles and pass of the Monarc TOT sling). The gray needles are the inferior needles that are used to attach the apical arms of the graft to the white line up near the ischial spines on each side. A macroporous polypropylene graft may be used as shown in the picture, or a biologic porcine graft is also available.

Needle Pass and Graft Attachment Points



Needle Paths and Attachment Points for Graft: The above diagram depicts the areas that the needles come through the sidewall of the pelvis and ultimately where the arms of the Perigee graft will be attached. The arms are brought back out the sidewall and provide a robust attachment through the fascia and the arcus (whiteline) itself. Anatomic dissections have shown these areas to be very safe distance away from any nerve or vascular structures.

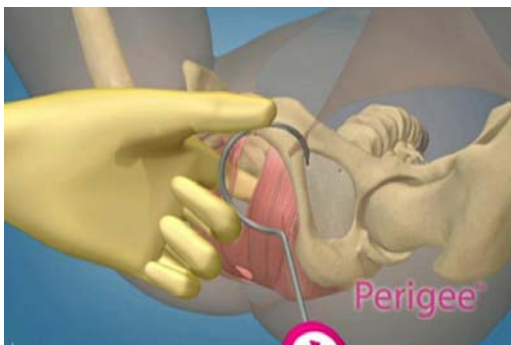


Fig A. Superior needle pass

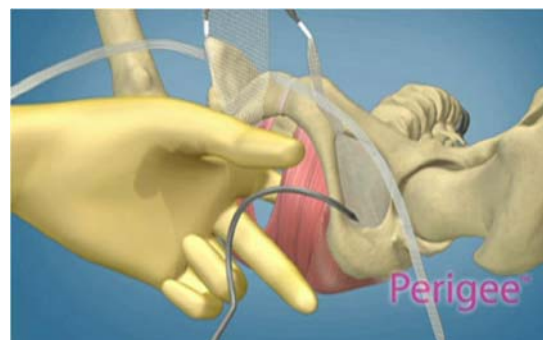
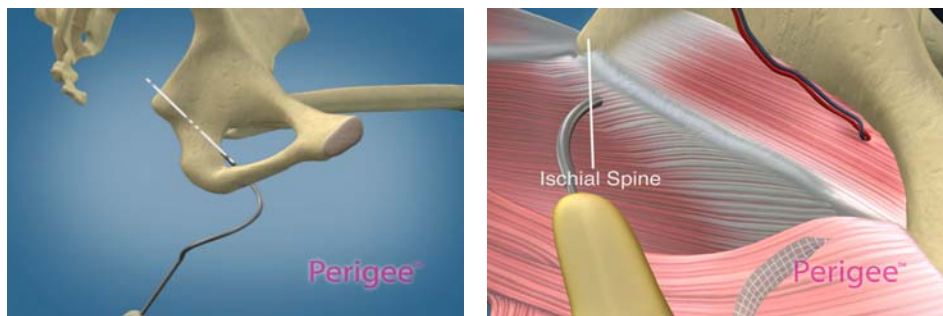
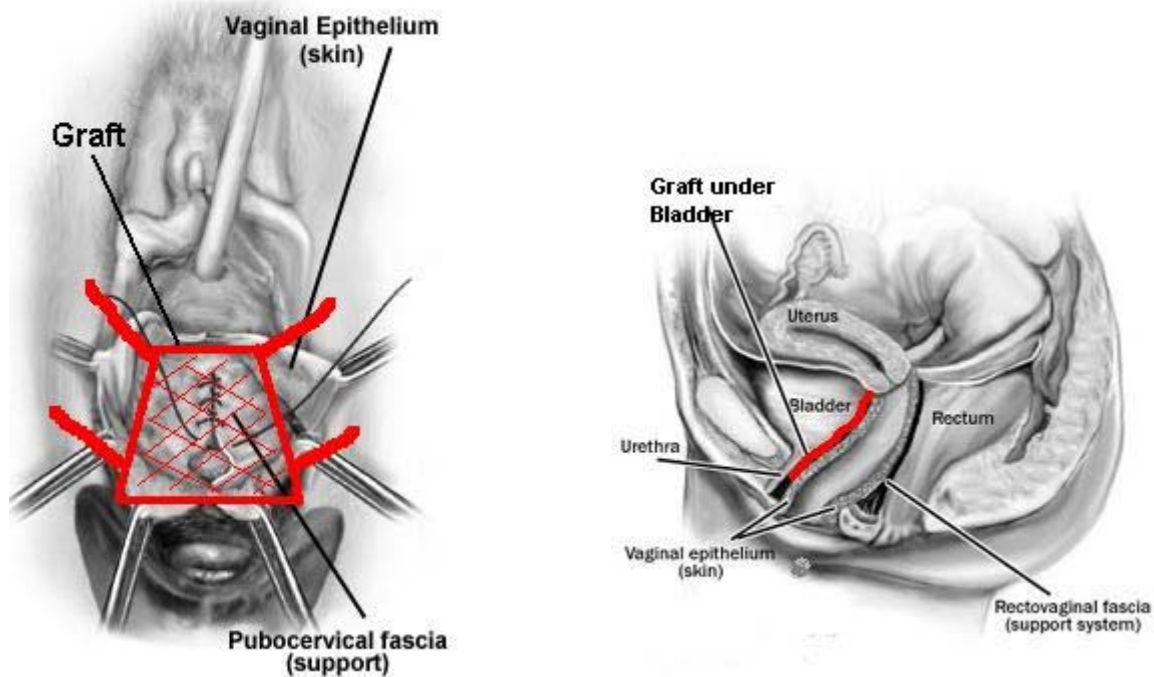


Fig B. Inferior/Apical needle pass

The above pictures depict the needle passes through the groin to enable connection of the anterior wall graft to the pelvic sidewalls. Very small incisions are made in the groins on each side. The superior incision is in the genitofemoral crease beneath the adductor longus tendon (same spot as Monarc TOT sling) and the inferior incision is 3cm inferior and 2cm lateral to this. Once the needles are passed, the arms of the graft are attached to the needles and pulled out through the groin incisions. The arms are then adjusted and tightened which adjusts the graft to support the bladder back up in its normal anatomic position. The tail of the graft is cut to fit the length of the patient's vagina and is attached up to the vaginal cuff (or pericervical ring if uterus is in place) prior to arm adjustment. The mesh graft forms a new floor under the bladder and supports it from the opening of the pubic bone up to the top of the vagina and from pelvic sidewall.



The Inferior or Apical needle pass is the NEW pass. It allows the surgeon to attach the apical portion of the graft up to the white line near the ischial spine (this is the hardest area to get a good safe attachment of a graft) which is up near the top of the vagina. As you can imagine, this is a very difficult area to get to and the Perigee enables us to get a strong attachment safely which gives a very anatomic repair. The needle is passed through the inferior incision and then through the inferior, medial portion of the obturator foramen and membrane. Once in the obturator space, the surgeon can palpate the needle on the other side of the levators and he/she then walks the needle up as close to the ischial spine as possible and brings it through the sidewall, with direct finger guidance at all times. The fingers placed vaginally allow correct positioning of the needle and also protect the bladder when bringing the needle into the vagina. The apical arm of the graft is then attached to the needle and it is brought back out the groin incision. Although some vault support may be obtained, this procedure is NOT designed to give vault support and if a patient has vault prolapse, this must be repaired at the same time.

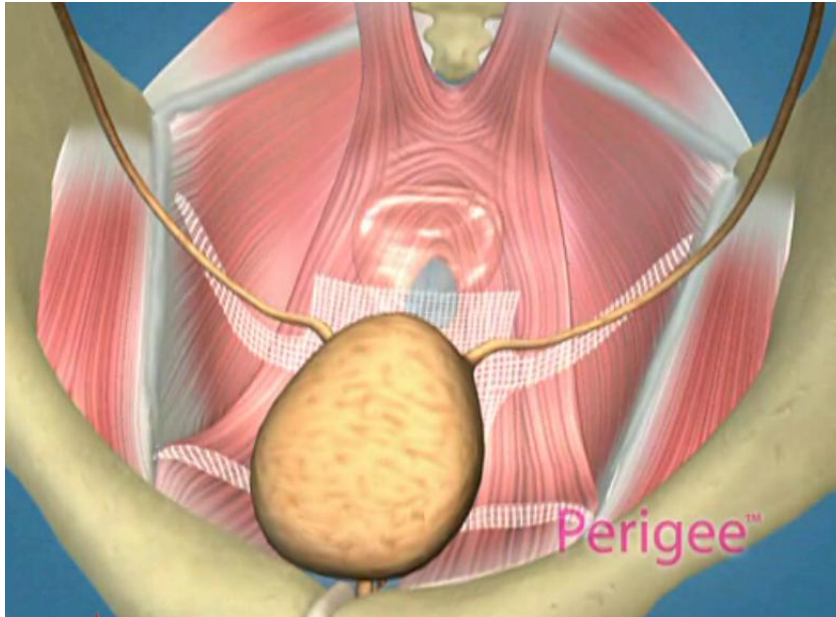


Graft in Position under Bladder: Once in place, the Perigee graft provides an entire new floor of support for the bladder from sidewall to sidewall. The skin of the vagina is closed over the graft, and the tissue ingrowth occurs very rapidly, making the graft become incorporated and part of the patient's anatomy very quickly. The vaginal skin is left thicker during dissection and no extra skin is cut off (like typical repairs) therefore reducing the risk of the graft extruding through the skin. Most patients and their partners cannot tell there is a graft in place once healed.

Risks and Complications

As with any surgical procedure, risks do exist. One must always weigh the benefits of graft use (increased cure rate) with the risks associated. For example if a patient has had 2 previous surgeries and they have failed, it is very doubtful that repeating the same procedure again will work, therefore it is very easy to state that this particular patient needs a graft for her repair and the benefits far outweigh the small risks associated. For the most part, risks associated with graft use in pelvic floor surgery are relatively small, however, again, as with any surgical procedure, risks do exist. A graft is a foreign body and therefore risks do include infection, rejection or erosion of the graft (into the bladder or urethra). These type of complications are very rare and the graft materials utilized today have been shown to be very well tolerated with minimal risk of this (all typically less than 1%) and of course experience of the surgeon also has an impact on these risks. Other risks include: bleeding, pain in the vagina or groins, vaginal scarring or pain with intercourse (risk of any pelvic floor surgery). One of the most common complications seen is extrusion of the graft through the vaginal skin. This can occur early with poor healing or later with poor tissue health and has been seen in 2% to 8% of patients. This is considered a minor complication and many times will heal on its own, however if it does

not and the graft is exposed, this area will need excised and repaired. This sometimes can even be completed in the office.



Atlanta Urogynecology Experience

Dr. Moore and Miklos have been performing anterior wall grafts for greater than 5 years and the transobturator Perigee procedure for more than 2 years now. They have once again been world leaders in this new minimally invasive technology to treat anterior wall prolapse (cystocele). They have been part of the United States multi-center trial evaluating and collecting research on the initial patients implanted with the procedure (Dr Moore is principal investigator of this U.S. trial directing prominent sites from all over the US including the Cleveland Clinic and Harvard). They have taught surgeons from all over the world and operated in Sweden, Finland, Spain, Italy, Greece, Turkey, Chile and Russia demonstrating the technique. Dr Moore has presented their research in the U.S. and internationally in Copenhagen, Montreal, Argentina and will be traveling to Greece and S. Africa in 2006 to operate and present research.

To date Dr Miklos and Moore have seen the same excellent short term clinical success that the Europeans and Australians have experienced. Results in the literature show that grafts have approximately 90% cure rate and the Perigee procedure has been shown to be consistent with this. Dr Moore and Miklos have not had any patients complain of postoperative pain in the area of the adductor muscles of the thigh, and no failures have

occurred to date (however these are short term results and unfortunately NO surgery will ever be 100% effective). No patients have had any nerve injury or major complications. The procedure takes less than 30 minutes to perform and can be completed under local or regional anesthesia. They have found this procedure to be very useful in patients with failed previous procedures, patients with previous retropubic surgery (such as Burch or Paravaginal repair), and in patients that are older or have large or severe prolapse. They also have found this approach useful in obese patients and women with retropubic scarring, in whom retropubic needle passage can be a challenge. This system will not treat urinary leakage, therefore if stress incontinence is an issue for a patient, this must be treated with concomitant sling (such as Monarc TOT sling), which can easily be completed at the same time.