

Use of Synthetic Mesh and Donor Grafts in Gynecologic Surgery

Neeraj Kohli, MD*, and John R. Miklos, MD

Address

*Mount Auburn Hospital, 300 Mount Auburn Street,
Suite 302, Cambridge, MA 02138, USA.
E-mail: nkohlimd@hotmail.com

Current Women's Health Reports 2001, 1:53-60
Current Science Inc. ISSN 1534-5874
Copyright © 2001 by Current Science Inc.

Traditional surgery for the correction of pelvic organ prolapse continues to result in suboptimal long-term cure rates. In an effort to improve clinical outcomes, various new surgical techniques have been proposed and use of synthetic and donor graft has been advocated. Although the technique of graft placement for the correction of anterior, posterior, and apical vaginal wall reconstruction is easy to perform, controversy exists regarding the optimal choice of material. Synthetic materials have the advantage of being readily available, cost-effective, and consistent in quality, but may present with significant complications, including infection and erosion. In contrast, autologous and heterologous donor grafts provide naturally occurring biomaterials that may undergo desired remodelling, but the in vivo tissue response is still not fully understood. The use of graft materials is still in an early period of evaluation and it is expected that its use will steadily rise with increasing experience and new product development. The following review analyzes our current experience with the use of graft materials in reconstructive pelvic surgery.

Introduction

Over the past four decades, there has been growing interest in the use of synthetic and donor graft materials for the surgical correction of pelvic prolapse, due to suboptimal long-term cure rates noted with traditional surgical techniques. Traditional techniques depend on plication of attenuated endopelvic fascia or accurate identification of site-specific defects. The use of graft interposition, either synthetic or donor, helps to reduce failure rates from breakdown of weakened tissue or failure to identify all present defects. Furthermore, readily available synthetic and donor products obviate the need for a separate tissue-harvesting procedure, reduce operative time and procedure charges, and provide materials that may be stronger than the patient's own fascial tissue. Despite these potential benefits, widespread use of grafts in gynecologic surgery is still in its infancy, due to poor under-

standing of the in vivo response to the graft material and a paucity of long-term clinical data supporting its use. Although the basic techniques of graft use are generally accepted, the indications for use and choice of material remain controversial.

Much of the initial data on synthetic mesh and donor allografts are derived from surgery research for repair of abdominal wall hernias, reconstruction of joints, and cosmetic treatment of burn victims. In gynecologic surgery, mesh and graft use can be categorized based on surgical procedures used primarily for the correction of pelvic prolapse. Synthetic and autologous materials have been extensively used in the areas of urology and urogynecology as materials for the suburethral sling procedure, and there is currently great controversy regarding the optimal material that provides good long-term results with minimal complications. The following review is limited to the current literature, techniques, and outcomes using both synthetic and autologous grafts in reconstructive pelvic surgery.

General Properties of Synthetic and Natural Graft Materials

Synthetic materials

Despite recent technologic advances in the design and study of synthetic materials, the ideal synthetic biocompatible material has yet to be developed. The use of synthetic mesh dates back to the mid-1950s when Cumberland [1] and Scales [2] reported their experience with synthetic materials for the treatment of ventral hernia repair and orthopedic prostheses. Since that time, extensive research has further defined critical in vitro and in vivo properties of synthetic materials with respect to implantation. Compared with autologous donor grafts, synthetic materials offer the advantage of ready availability, lower cost, consistent strength, and predictable in vivo tissue response. Disadvantages of synthetic material include failure of remodeling, limited stretch properties, and potential of erosion or infection.

All mesh materials should be chemically and physically inert, noncarcinogenic, mechanically strong, and easily fabricated and sterilized. They should all have a high minimum tensile strength (> 50 N) that will provide adequate strength to withstand pressure placed on the pelvic floor during episodes of increased abdominal pressure. Synthetic mesh materials vary in their ability to withstand




Figure 1. Pore configuration of commonly used synthetic meshes. A, Marlex; B, Mersilene; C, Prolene; D, Bore-Tex.

infection and promote healing depending on pore size. Brun *et al.* [3] compared the mechanical and biologic properties of polyethylene terephthalate (Mersilene; Ethicon, Somerville, NJ), polypropylene (Marlex; Phillips Sumika, Houston, TX), polytetrafluoroethylene (Teflon; DuPont, Wilmington, DE), and expanded polytetrafluoroethylene (Gore-Tex; Gore, Newark, DE) and found Gore-Tex to have large sections or nodes which are interconnected with fibrils. Prolene mesh is composed of a monofilament material which provides the theoretic advantage of increased interstices allowing polymorphonuclear leukocyte (PMN) and macrophage entry in addition to bacterial colonization. In contrast, the small interstices of multifilament mesh ($< 10 \mu\text{m}$) allow passage of bacteria but block larger cells such as macrophages and PMNs.

In addition to potential for infection, porosity characteristics including number, size, and shape of the pores may correlate with subsequent development of fibrous ingrowth into the mesh. In a comparison of commonly used synthetic materials, Pourdeyhimi [4] found Mersilene to be the most porous when compared with Teflon and Marlex. Teflon was noted to have the largest pore diameter ($1630 \mu\text{m}$), which correlates with *in vivo* tissue characteristics that reduce the ability of both Teflon and Gore-Tex to effectively bond to surrounding tissues. A comparison of mesh pore configuration is illustrated in Figure 1.

Mesh flexibility is another important property that may correlate with clinical complications. Chu and Welch [5] demonstrated Marlex mesh to have the highest stiffness factor compared with Mersilene and Teflon. This physical characteristic may explain the high rate of mesh-related complications in general surgery related to Marlex, and its propensity for injury to adjacent tissues. These include mesh extrusion, fistula formation, and visceral erosion [6]. This characteristic is especially important in gynecologic

surgery in which the synthetic mesh material needs to be soft and flexible to accommodate the natural stretching of the vaginal tissue during sexual intercourse. Rigidity of the mesh materials may lead to erosion and dyspareunia.

Natural materials

Autologous materials, including cadaveric fascia, human and porcine dermis, and small intestinal submucosa, have recently received greater attention for use in reconstructive pelvic surgery due to technologic advances in tissue harvesting and processing. Critical tissue properties of these tissues include tensile strength, antigenicity, and *in vivo* tissue remodeling. Compared with synthetic mesh materials, autologous donor grafts offer the advantage of *in vivo* tissue remodeling, histologic similarity to native vaginal tissue, and reduced incidence of erosion. Disadvantages include limited supply with increased cost, inconsistency of tissue strength, and lack of long-term outcome data.

The tensile strength of allograft tissues is important for strength and durability of pelvic prolapse procedures. In their study of tissue strength comparing autologous and cadaveric allografts for pubovaginal sling, Lemer *et al.* [7•] reported no statistical difference in both maximum load to failure (MLF) and stiffness among autologous rectus fascia, solvent dehydrated cadaveric fascia lata, and cadaveric dermal grafts, but did report reduced MLF and stiffness in the freeze-dried cadaveric fascia lata. MLF ranged from 25 to 33 N/mm. This and similar studies suggest that the processing technique had significant effect on tissue mechanical properties and *in vivo* response.

Antigenicity of the donor graft will affect *in vivo* tissue response as well as infection transmission. Although most commercially available autologous and heterologous grafts are acellular, infection transmission of viral particles (prions) still remains a potential concern. Fitzgerald *et al.*

Table 1. Commercially available meshes and grafts

Base component	Trade name	Type/processing
Synthetic meshes		
Polypropylene	Marlex (CR Bard)	Monofilament
	Prolene (Ethicon)	Monofilament
	Atrium (Atrium)	Monofilament
Polytetrafluoroethylene (PTFE)	Teflon (CR Bard)	Monofilament
Expanded PTFE	Gore-Tex (WL Gore)	Multifilament
Polyethylene terephthalate	Mersilene (Ethicon)	Multifilament
Polyglycolic acid (absorbable)	Dexon (Davis & Geck)	Multifilament
Polyglactin 910 (absorbable)	Vicryl (Ethicon)	Multifilament
Natural grafts		
Human dermis	Repliform (Boston Scientific)	Freeze-dried/chemical
	Duraderm (CR Bard)	Freeze-dried
	Duraderm (CR Bard)	Freeze-dried/irradiated
Human fascia lata	Tutoplast (Mentor)	Tutoplast process
Porcine small intestinal submucosa	Stratasis (Cook)	Freeze-dried

Atrium, Canton, OH; Boston Scientific, Quincy, MA; CR Bard, Murray Hill, NJ; Cook, Bloomington, IN; Davis & Geck, Danbury, CT; Ethicon, Somerville, NJ; Mentor, Santa Barbera, CA; WL Gore, Newark, DE.

[8] documented successful human leukocyte antigen (HLA) typing in both freeze dried and chemically processed cadaveric fascia lata, but was unsuccessful in identification of donor antigens on cadaveric dermal graft due to material interference with the study assay. However, host antigens replaced all donor antigens after implantation. Further research and clinical experience with widespread use of the various donor graft materials is still required before definitive conclusions regarding antigenicity and infection transmission can be made.

In vivo tissue remodeling is the primary goal of all natural, acellular biomaterials used in gynecologic surgery. Ideally, the acellular graft provides a stable three-dimensional structure that attracts host cells and acts as an interactive scaffold for host cell migration, neovascularization, and tissue remodeling. However, studies to date have revealed that the implanted graft materials may either go through encapsulation with graft fibrosis, breakdown with loss of support, or the desired incorporation with tissue remodeling. In vivo tissue response may be related to preimplantation processing, which may alter the structural integrity of the graft and promote host cell identification of the implant as a foreign body rather than a primordial matrix for remodeling. Fitzgerald *et al.* [9•] have described sudden short-term failure of allograft suburethral slings in up to 20% of patients due to in vivo degeneration without tissue remodeling. Follow-up histologic studies revealed fibroblast proliferation and degeneration within the graft. To date, there are few studies in the gynecology or urology literature assessing the in vivo tissue response when donor graft is implanted in the human vagina. As with antigenicity and mechanical properties, it may depend on the graft material as well as preimplantation processing techniques. Further research in this area is currently in progress.

Despite the various controversies and incomplete information regarding the general properties of both synthetic and natural materials available, there is increasing use of such grafts in gynecologic surgery in the hopes of improving long term clinical outcomes. Further research and continuing product development will provide increasing data regarding the optimal graft for use. A list of currently available synthetic and natural grafts is provided in Table 1.

Anterior Vaginal Wall Reconstruction

Anterior vaginal wall reconstruction concentrates on the surgical repair of the cystocele, a hernia that occurs when the bladder bulges into the vagina due to attenuation or site-specific defect of the pubocervical fascia. Traditionally, the cystocele has been repaired with an anterior colporrhaphy requiring plication of the attenuated pubocervical fascia with a series of sutures from the bladder neck to the bladder base. Over the past decade, Richardson *et al.* [10••] have popularized the paravaginal defect repair for lateral detachment of the pubocervical fascia from the lateral sidewall. This repair can be performed abdominally, vaginally, or laparoscopically. The use of graft material to reinforce either the midline plication repair or the lateral paravaginal defect repair generally involves anchoring of the graft material to the lateral pelvic sidewall or endopelvic fascia using a series of interrupted sutures from the ischial spine to the bladder neck (Fig. 2). This technique has been a recent addition to the gynecologic literature with current studies analyzing few patients with limited long-term outcome data.

Synthetic materials

A variety of synthetic materials have been used for the surgical correction of cystocele. The largest series to date is

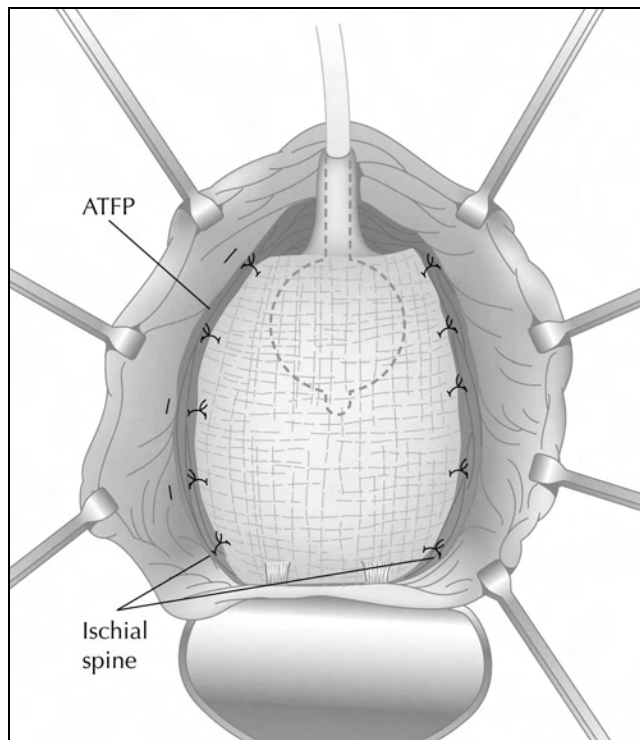


Figure 2. Anterior repair with mesh/graft. The material is secured to the arcus tendineus fascia pelvis bilaterally using a series of interrupted sutures.

from Flood *et al.* [11] reporting their 12-year experience with 142 women undergoing a modified anterior colporrhaphy reinforced with Marlex mesh. They reported a 100% success rate for cystocele and 74% success rate for urinary stress incontinence with mean follow-up of 3.2 years. They reported no significant intraoperative complications. Migliari [12] reported the use of tension free Prolene (Ethicon, Somerville, NJ) mesh in the treatment of advanced (grade III) cystocele in 12 patients with coexisting stress urinary incontinence. The Prolene mesh was fixed in a four-point fashion with absorbable suture to the urethropelvic ligaments anteriorly and to the cardinal ligaments posteriorly. On mean follow-up of 20.5 months (range, 15–32 months), nine patients had complete cure, whereas the remaining three had a mild asymptomatic grade I cystocele on exam. No significant postoperative complications were reported [12]. In a prospective randomized trial of 125 patients utilizing polyglactin 910 mesh to augment standard anterior colporrhaphy, Koduri *et al.* [13] reported a failure rate of 13% in the colporrhaphy alone group compared with 1% in the colporrhaphy-mesh group on 1-year follow-up. Subjectively, both groups improved equally.

Natural materials

Despite increasing widespread use, there are limited data regarding the complications and outcomes of donor grafts for the treatment of cystocele. Chaikin *et al.* [14] reported a 100% cure rate in 17 patients utilizing solvent-dehydrated

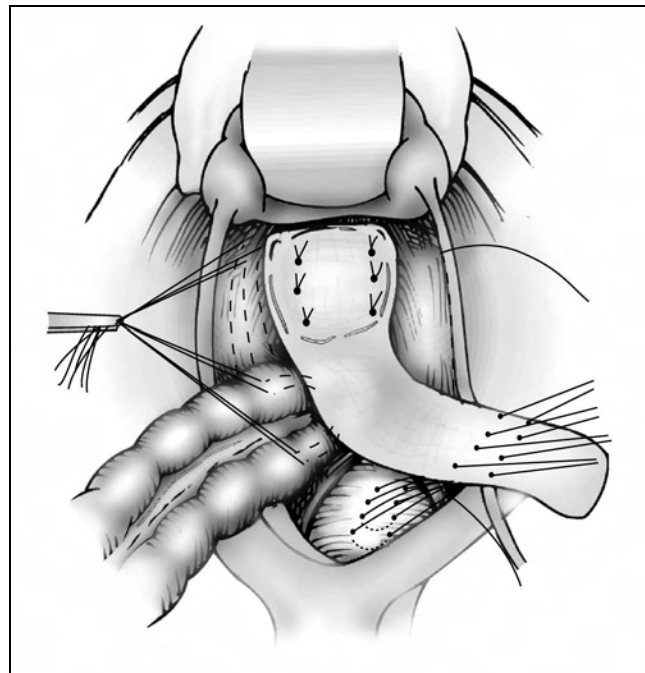


Figure 3. Abdominal sacrocolpopexy with mesh/graft. The proximal end of the mesh is secured to the Sacral promontory and the distal end of the mesh is secured to the fascia of the vaginal apex.

cadaveric fascia to reinforce a conventional anterior repair. On short-term follow-up of 7.4 months, there were no postoperative complications related to the material or technique. Kobashi *et al.* [15] reported 71% patient satisfaction scores in 54 women undergoing transvaginal cadaveric prolapse repair with sling (CaPS procedure) with mean 8-month follow-up. One case of osteitis pubis and three cases of mild recurrent cystocele were noted. Myers and Arya [16] recently presented their data using a cadaveric dermal graft (Alloderm; LifeCell, Branchburg, NJ) in six patients with grade III cystocele. No recurrence of cystocele was noted on short term follow-up ranging from 6 to 24 months. No intraoperative complications were noted, but one patient had vaginal erosion of a permanent suture knot which was removed in the office without sequelae.

Vaginal Vault Suspension

Although more than 43 different operations have been described for the surgical correction of post-hysterectomy vaginal vault descensus [17], none has the extensive use and historic data comparable with the abdominal sacrocolpopexy (ASC). In this procedure, a graft is used to connect the vaginal apex to the anterior longitudinal ligament of the S2 or S3 sacral vertebrae (Fig. 3). The attachment of the graft to the sacrum is standardized with a series of interrupted permanent sutures or bone anchors, but the configuration of the graft at the vaginal apex has been modified frequently to optimize cure rates and minimize graft complications including erosion and enterocele.

Synthetic materials

Due to the length and width (approximately 10 cm × 3 cm) of the graft, synthetic materials have long been used for sacrocolpopexy before donor grafts became widely available. In 1985, Addison *et al.* [18] reported a series of Mersilene mesh sacrocolpopexies with no mesh-related complications in 40 women with a mean follow-up of 39 months (range, 6 months–12 years). A 96% subjective cure rate was reported. A subsequent corollary study, published by Timmons *et al.* [19•] in 1992, reported an equally impressive 99% cure rate in 163 patients undergoing Mersilene mesh sacrocolpopexy with median follow-up of 33 months (range, 9 months–18 years). Recurrent vault prolapse was noted in two patients and enterocele in three others. Again, no significant mesh-related complications were reported.

Mesh-related complications include infection, bowel obstruction, and erosion. Mesh erosion is associated with use of synthetic materials for the suspensory graft, which reduce operative time and simplify the procedure by eliminating additional fascia harvesting procedures. In addition, these materials often are stronger than the patient's own fascial tissues. Timmons and Addison [20] reported a Mersilene mesh erosion rate of 3% (13/375) with a highly variable time to presentation (6 weeks–6 years, average 21 months). All patients were symptomatic with complaints of blood-tinged vaginal discharge. Kohli *et al.* [21] reported a cumulative erosion rate of 12% (2 suture erosions and 5 mesh erosions) in 57 patients undergoing ASC using Marlex with mean postoperative follow-up of 19.9 months (range, 1–50 months). Average time to erosion was 14 months (range, 4–24 months) and the authors concluded that there was no safe time zone following surgery after which mesh erosion was less frequent. All patients with mesh erosion required surgical intervention with excision of the mesh and vaginal advancement. In a comprehensive review of the use of synthetic mesh in gynecologic surgery, Iglesia *et al.* [22••] reported erosion rates of at least 9% with Marlex, Gore-Tex, and Mersilene, and up to 11% with Teflon. The overall revision and removal rate, based on a review of 592 sacrocolpopexies from various series, was 2.7%.

Management of eroded synthetic mesh is controversial. Addison *et al.* [18] recommend transvaginal removal of the eroded mesh, despite a high rate of recurrent erosion, as complete mesh resection via the abdominal approach can be associated with life-threatening hemorrhage from the sacral vessels. Timmons *et al.* [19•] reported successful conservative treatment (pelvic rest and vaginal estrogen cream) for suture erosion but advocated mesh excision with vaginal advancement for mesh erosion. Laparoscopic removal of eroded Gore-Tex graft has also been reported [23]. Cundiff *et al.* [24•] described a modified abdominal sacrocolpoperineopexy that was then further evaluated by Visco *et al.* [25], who found a greater incidence of mesh erosion compared with traditional sacrocolpopexy. The authors postulated that the combined vaginal-abdominal approach required to attach the distal portion of the mesh to the perineal body

may have contributed to the higher erosion rate in the sacrocolpoperineopexy group. This work would suggest that procedural details, in addition to the type of mesh used, may influence erosion and other mesh-related complications. Other mesh-related complications, including erosion into the bladder and ascending sacral osteomyelitis, have been reported but are extremely rare [26].

Despite reports of erosion and infection, complications associated with synthetic mesh use in abdominal sacrocolpopexy are still rare, and ready availability of the material, as well as reduced costs, make it the preferred option for graft use in vaginal vault suspension procedures. Success rates range from 95% to 100% on long-term follow-up with minimal complications. Based on current literature comparing relative erosion rates of the different synthetic materials, there is little consensus regarding the optimal choice of synthetic material. Current practice depends on surgeon preference, cost profile, and operating room availability.

Natural materials

Given the long experience and relatively low rate of serious complications with the use of synthetic materials in the abdominal sacrocolpopexy procedure, there are few data regarding the use of autologous or heterologous biologic graft materials and their associated outcomes and complications. Small series utilizing rectus fascia, dermal grafts, and dura mater have been reported with cure rates comparable to those using synthetic material [27–29]. Culligan *et al.* [30] reported their experience using an acellular human dermal graft for abdominal sacrocolpopexy in 32 patients with longitudinal follow-up over 1 year. Initial results indicate that the dermal graft is an acceptable material for abdominal sacrocolpopexy and is associated with no significant postoperative complications.

Posterior Vaginal Wall Reconstruction

Posterior vaginal reconstruction mainly corrects a rectocele, a hernia with bulging of the rectum into the vagina. Traditionally, rectocele has been treated with posterior colporrhaphy, which consists of a midline plication of the rectovaginal fascia through a transvaginal approach. In an effort to improve anatomic and functional cure rates, site-specific defect repair of the rectovaginal septum for the treatment of rectocele has recently been introduced. Compared with traditional posterior colporrhaphy which assumes generalized laxity of the rectovaginal fascia, the site-specific theory postulates discrete breaks as the etiology of the vaginal wall prolapse. Unfortunately, both techniques have limitations including adequate fascial strength, accurate identification of discrete fascial defects, and restrictions with regard to lateral incorporation of levator muscle tissue. Reported success rates with the traditional repair range from 65% to 75% on medium-term follow-up (1–2 years) with significant decline beyond 3 years [31]. Recent work has been focused on utilizing graft

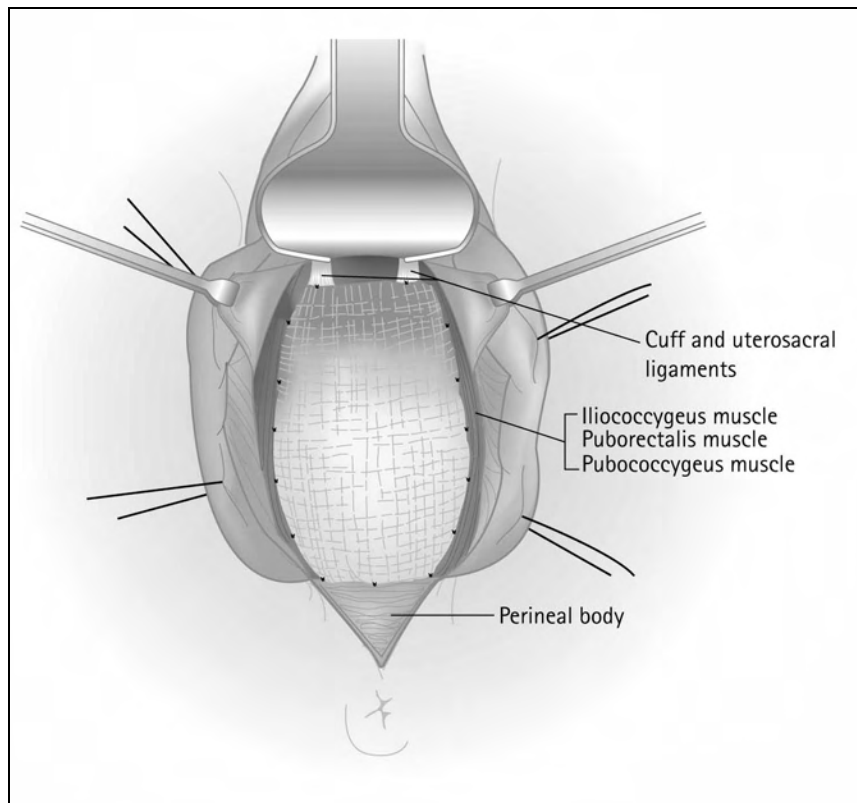


Figure 4. Posterior repair with mesh/graft. The material is secured bilaterally to the levator ani muscles, distally to the perineal body, and proximally to the uterosacral ligaments or fascia of the vaginal apex.

materials to augment the rectovaginal septum and improve long-term surgical cure rates. The procedure is performed by recreating the rectovaginal septum using an allograft attached to the levator ani muscles bilaterally, the pubocervical fascia/vaginal apex proximally, and the perineal body distally (Fig. 4).

Synthetic materials

A variety of synthetic materials have been used for posterior wall reconstruction in small series. In 1993, Parker and Phillips [32] reinforced the rectovaginal septum with Marlex mesh in four women with advanced rectoceles. No mesh related complications were noted during 18-month follow-up. Fox and Stanton [33] have reported their experience with the use of Mersilene mesh to augment traditional rectocele repair in 29 women followed for 14 months. The majority of women had previous rectocele repair with recurrence of their prolapse. All women with stage II and stage III vault prolapse were corrected, with an increase in stage I prolapse from 20% to 27%. All women with stage II and stage III rectocele were corrected with a decrease in stage I prolapse from 36% to 7%. The only significant intraoperative complication was a cystotomy. One mesh became infected postoperatively, requiring removal [33]. Watson *et al.* [34] have described their experience with transperineal repair of symptomatic rectocele with Marlex mesh in nine women with long-term follow-up of 29 months. Eight of the nine women achieved successful evacuation after surgery without the need for vaginal digitation. Rectocele size, depth, and the percent of barium trapped in the rectocele on

proctography were all improved. No mesh-related complications were reported [34].

Laparoscopic rectocele repair using a polyglactin mesh was first described by Lyons and Winer [35] with an 80% cure rate in 20 women followed at 3-month intervals for 1 year. No long-term complications were noted. Although associated with high success rates, the procedure is technically challenging and deviates from the traditional vaginal approach to rectocele adopted by most gynecologic surgeons. Permanent synthetic mesh appears to be an attractive material for use in rectocele repair but the gynecologic surgeon should be cautious for several reasons. First, synthetic mesh may be associated with higher rates of infection and erosion. Second, few synthetic materials have stretch properties which may mimic the natural elasticity of the vaginal wall during sexual intercourse. Thus, use of restrictive synthetic materials may be associated with higher rates of dyspareunia following augmented rectocele repair. Further research regarding the use of synthetic materials for this application is currently in progress.

Natural materials

Similar to anterior wall repair, there are few data regarding the use of natural donor grafts in posterior wall reconstruction. Oster and Astrup [36] first described the use of a dermal transplant for the treatment of large and recurrent rectocele, and Zacharin [37] reported his initial experience with full-thickness vaginal epithelium graft for rectocele repair in a limited number of patients. Recently, Kohli and Miklos [38] have reported the largest series to date with 57

patients undergoing augmented rectocele repair using a cadaveric dermal graft over a 2-year period. Average follow-up was 11 months. Average patient age in the follow-up group was 63.6 ± 10.9 years (range, 33–79 years) and average parity was 2.8 ± 1.5 (range, 0–7 years). No major intraoperative complications (hollow viscous injury, blood loss greater than 500 cc, or transfusion) or postoperative complications (infection, abscess, or hematoma) were noted. No graft-related complications such as rejection, erosion, infection, or fistula formation were noted during the follow-up period. Using the Pelvic Organ Prolapse Quantification score to assess the severity of prolapse pre- and postoperatively, the average measurement of point A_p was 0.25 preoperatively and -2.6 postoperatively, whereas point B_p was 0.9 preoperatively and -2.6 postoperatively. Using a point A_p measurement of -0.5 or greater to define surgical failure, 54 of 57 (95%) of women were noted to have surgical cure at follow-up [38]. These authors have also described the use of dermal graft in the repair of complicated rectovaginal fistula [39].

Despite a lack of long-term data, this technique may have multiple benefits over traditional posterior colporrhaphy or site-specific defect repair. First, the augmentation is done in addition to, not in lieu of, a standard rectocele repair using a sturdy natural graft. Second, the technique is effective regardless of inherent strength of the rectovaginal septum or accurate and complete identification of site-specific fascial defects. Third, it obviates the need for extensive lateral plication and subsequent levatorplasty. The technique has been rapidly adopted by many pelvic surgeons with utilization of a broad range of graft materials. Further data regarding efficacy and complications are still required prior to widespread adoption.

Conclusions

Long-term cure rates of vaginal wall prolapse continue to be suboptimal. This may be due to poor tissue strength, inadequate surgical repair, or continued stress due to chronic straining, obesity, and sustained increases in intra-abdominal pressure. Regardless of the etiology, improved surgical techniques and use of graft materials, either synthetic or donors, have the potential of improving our long-term success rates. Most procedures incorporating graft use are easy to learn and incorporate basic principles of vaginal surgery already mastered by the average gynecologic surgeon. Complications related to graft use may be dependent on several factors including the surgical technique, graft material, and host (patient) response factors. Long-term data comparing the various graft materials for specific procedures in terms of outcomes and complications are lacking. Increased experience should lead to better long term data to support choice of material and optimal surgical technique. At this point, no optimal tissue has been determined based on historic data. According to Iglesia *et al.* [22], "the ideal synthetic mesh material for pelvic surgery, one that induces minimal foreign body

reaction with minimal risk of infection, rejection, and erosion, has yet to be developed." Further work in this area is currently in progress and should provide additional information in the near future. Exciting innovations including new synthetic materials, mixed mesh-graft composition, and cloning of host cell grafts may completely change the landscape of gynecologic surgery. In the meantime, surgeons may want to consider adopting use of graft techniques to improve surgical results with care given to carefully monitor complications.

References and Recommended Reading

Papers of particular interest, published recently, have been highlighted as:

- Of importance
 - Of major importance
1. Cumberland VH: A preliminary report on the use of prefabricated nylon weave in the repair a ventral hernia. *Med J Aust* 1952, 1:143–144.
 2. Scales JT: Materials for hernia repair. *Proc Roy Soc Med* 1953, 46:647–652.
 3. Brun JL, Bordenave K, Lefebvre F, *et al.*: Physical and biological characteristics of the main biomaterials used in pelvic surgery. *Bio-Med Mat Eng* 1992, 2:203–225.
 4. Pourdeyhimi B: Porosity of surgical mesh fabrics: new technology. *J Biomed Mat Res* 1985, 19:903–916.
 5. Chu CC, Welch L: Characterization of morphologic and mechanical properties of surgical mesh fabrics. *J Biomed Mat Res* 1985, 19:903–916.
 6. Voyles CR, Richardson JD, Bland KI, *et al.*: Emergency abdominal wall reconstruction with polypropylene mesh: short-term benefits vs. long-term complications. *Ann Surg* 1981, 194:219–223.
 7. Lemer ML, Chaikin DC, Blaivas JG: Tissue strength analysis of autologous and cadaveric allografts for the pubovaginal sling. *Neurourol Urodyn* 1999, 18:497–503.
- Benchmark research analyzing the mechanical tissue properties of various donor graft materials in a comparative fashion.
8. Fitzgerald MP, Mollenhauer J, Brubaker L: The antigenicity of fascia lata allografts. *BJU Int* 2000, 86:826–828.
 9. Fitzgerald MP, Mollenhauer J, Brubaker L: Failure of allograft suburethral slings. *BJU Int* 1999, 84:785–788.
- First study analyzing the in vivo tissue response of donor graft with respect to short term failure and correlation to histologic appearance on follow-up.
10. Richardson CA, Edmonds PB, Williams NL: Treatment of stress urinary incontinence due to paravaginal fascial defect. *Obstet Gynecol* 1981, 57:352–357.
- Landmark paper describing the concepts of paravaginal defect repair and establishing the framework for site-specific defects in the etiology of pelvic organ prolapse.
11. Flood CG, Drutz HP, Waja L: Anterior colporrhaphy reinforced with Marlex mesh for the treatment of cystoceles. *Int Urogynecol J Pelvic Floor Dysfunct* 1998, 9:200–204.
 12. Migliari R: Treatment results using a mixed fiber mesh in patients with grade IV cystocele. *J Urology* 1999, 161:1255–1258.
 13. Koduri S, Lobel RW, Winkler HA, *et al.*: Prospective randomized trial of Polyglactin 910 mesh to prevent recurrence of cystoceles and rectoceles. Proceedings of the 25th Annual Meeting of the International Urogynecological Association 2000. *Int Urogynecol J Pelvic Floor Dysfunct* 2000, 11(Suppl):S80.
 14. Chaikin DC, Groutz A, Blaivas JG: The use of cadaveric solvent dehydrated fascia lata for cystocele repair-preliminary results. Proceedings of the 25th Annual Meeting of the International Urogynecological Association 2000. *Int Urogynecol J Pelvic Floor Dysfunct* 2000, 11(Suppl):S86.

15. Kobashi KC, Beck TP, Mee SL, Leach GE: **Update on our experience with the transvaginal cadaveric prolapse repair with sling.** Proceedings of the 25th Annual Meeting of the International Urogynecological Association 2000. *Int Urogynecol J Pelvic Floor Dysfunct* 2000, **11(Suppl)**:S87.
16. Myers DI, Arya LA: **Alloderm graft for cystocele repair.** Proceedings of the 21th Annual Scientific Meeting of the American Urogynecologic Society 2000. *Int Urogynecol J Pelvic Floor Dysfunct* 2001, **12(Suppl)**:S60.
17. Ridley JH: **A composite vaginal vault suspension using fascia lata.** *Am J Obstet Gynecol* 1976, **126**:590-596.
18. Addison WA, Livengood CH, Sutton GP, *et al.*: **Abdominal sacrocolpopexy with Mersilene mesh in the retroperitoneal position in the management of post hysterectomy vaginal vault prolapse and enterocele.** *Obstet Gynecol* 1985, **153**:140-146.
- 19.● Timmons CM, Addison WA, Addison SB, *et al.*: **Abdominal sacrocolpopexy in 163 women with post hysterectomy vaginal vault prolapse and enterocele: evolution of operative techniques.** *J Reprod Med* 1992, **37**:323-327.
One of the largest series to date analyzing the sacrocolpopexy operation in terms of results and complications.
20. Timmons MC, Addison WA: **Mesh erosion after abdominal sacrocolpopexy.** *J Pelvic Surg* 1997, **3**:75-80.
21. Kohli N, Walsh PM, Roat TW, Karram MM: **Mesh erosion after abdominal sacrocolpopexy.** *Obstet Gynecol* 1998, **92**:999-1004.
- 22.●● Iglesia CB, Fenner DE, Brubaker LB: **The use of mesh in gynecologic surgery.** *Int Urogynecol J* 1997, **8**:105-115.
Comprehensive review of synthetic material use in suburethral sling and sacrocolpopexy procedures, with detailed analysis of materials and summary of results and complications categorized by synthetic material.
23. Atlas I, Hallum AV, Hatch K: **Laparoscopic repair of vaginal Gore-Tex erosion after sacrocolpopexy.** *J Gynecol Surg* 1995, **11**:177-180.
- 24.● Cundiff GW, Harris RL, Coates K, *et al.*: **Abdominal sacral colpoperineopexy: a new approach for correction of posterior compartment defects and perineal descent associated with vaginal vault prolapse.** *Am J Obstet Gynecol* 1997, **177**:1345-1353.
Description and clinical experience of a new technique combining current anatomic principles with traditional sacrocolpopexy operation.
25. Visco AG, Weidner AC, Berber MD, *et al.*: **Vaginal mesh erosion after abdominal sacral colpopexy.** *Am J Obstet Gynecol* 2001, **184**:297-302.
26. Pastner B: **Mesh erosion into the bladder after abdominal sacrocolpopexy.** *Obstet Gynecol* 2000, **95**:1029.
27. Hendee AE, Berry CM: **Abdominal sacrocolpopexy for vaginal vault prolapse.** *Clin Obstet Gynecol* 1981, **24**:1217-1226.
28. Pelosi MA, Apuzzio J, Gowda V, Patel RC: **Use of dermal graft in the surgical repair of vaginal vault prolapse.** *Obstet Gynecol* 1980, **55**:385-388.
29. Lansman HH: **Posthysterectomy vault prolapse: sacral colpopexy with dura mater graft.** *Obstet Gynecol* 1984, **63**:577-582.
30. Culligan P, Hamons G, Heit M: **The use of acellular dermal grafts in reconstructive pelvic surgery.** Proceedings of the 21th Annual Scientific Meeting of the American Urogynecologic Society 2000. *Int Urogynecol J Pelvic Floor Dysfunct* 2001, **12(Suppl)**:S55.
31. Kahn MA, Stanton SL: **Posterior colporrhaphy: its effects on bowel and sexual function.** *Br J Obstet Gynecol* 1997, **104**:82-86.
32. Parker MC, Phillips RKC: **Repair of rectocele using Marlex mesh.** *Ann Roy Coll Surg Engl* 1993, **75**:193-194.
33. Fox SD, Stanton SL: **Vault prolapse and rectocele: assessment of repair using sacrocolpopexy with mesh interposition.** *BJOG* 2000, **107**:1371-1375.
34. Watson SJ, Loder PB, Halligan S, *et al.*: **Transperineal repair of symptomatic rectocele with Marlex mesh: a clinical, physiological and radiologic assessment of treatment.** *J Am Coll Surg* 1996, **183**:257-261.
35. Lyons TL, Winer WK: **Laparoscopic rectocele repair using polyglactin mesh.** *J Am Assoc Gynecol Laparosc.* 1997, **4**:381-384.
36. Oster S, Astrup A: **A new vaginal operation for recurrent and large rectocele using dermis transplant.** *Acta Obstet Gynecol Scand* 1981, **60**:493-495.
37. Zacharin RF: **Free full-thickness vaginal epithelium graft in correction of recurrent genital prolapse.** *Aust N Z J Obstet Gynaecol* 1992, **32**:146-148.
38. Kohli N, Miklos JR: **Site specific rectocele repair augmented with a cadaveric dermal graft.** Proceedings of the 21th Annual Scientific Meeting of the American Urogynecologic Society 2000. *Int Urogynecol J Pelvic Floor Dysfunct* 2001, **12(Suppl)**:S9.
39. Miklos JR, Kohli N: **Rectovaginal fistula repair utilizing a cadaveric dermal allograft.** *Int Urogynecol J Pelvic Floor Dysfunct* 1999, **10**:405-406.